



MASSACHUSETTS  
GENERAL HOSPITAL

HARVARD  
MEDICAL SCHOOL



## CASE 6

G. Petur Nielsen, M.D.

Department of Pathology

Massachusetts General Hospital

Boston, MA

Professor of Pathology

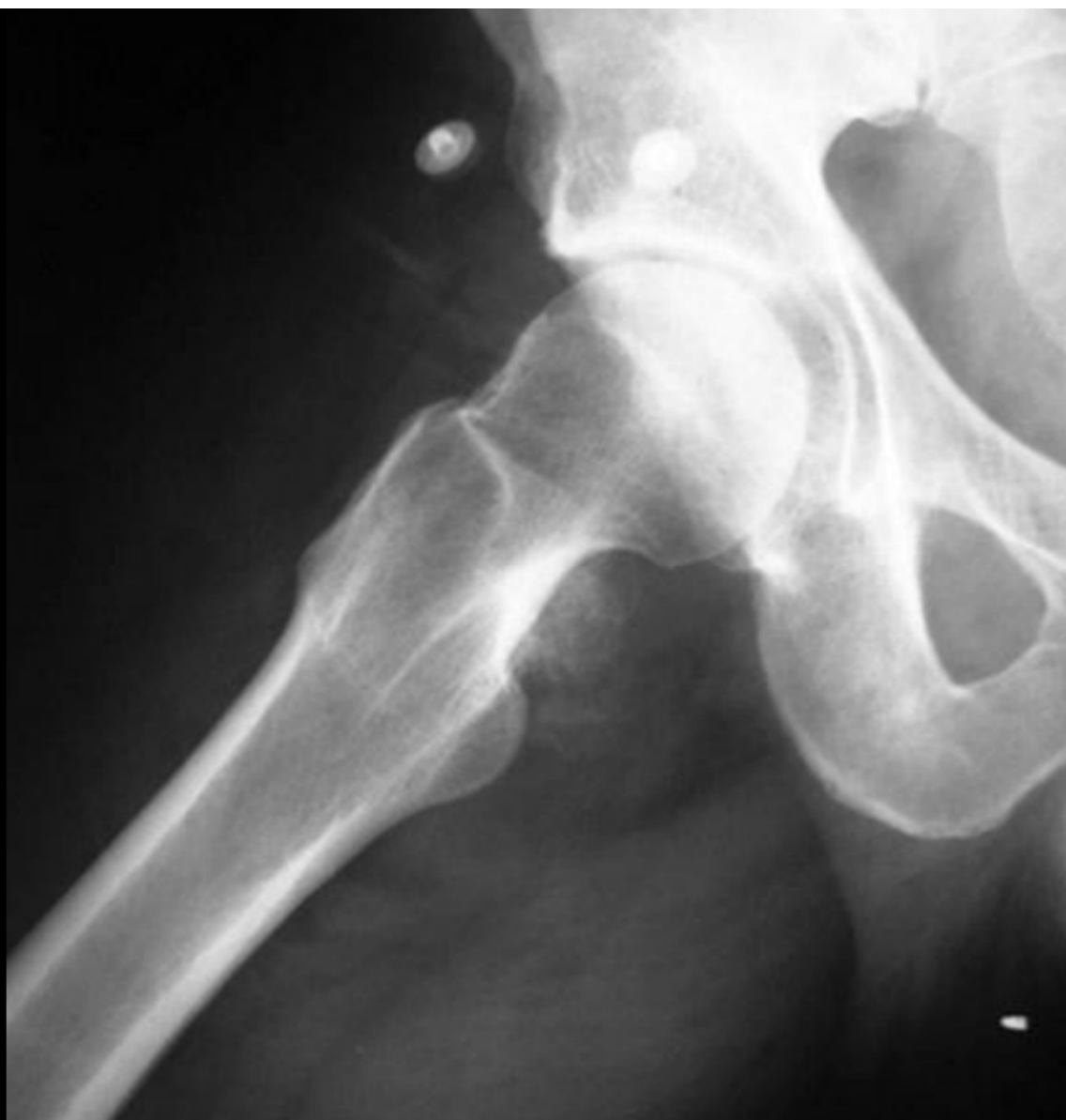Harvard Medical School

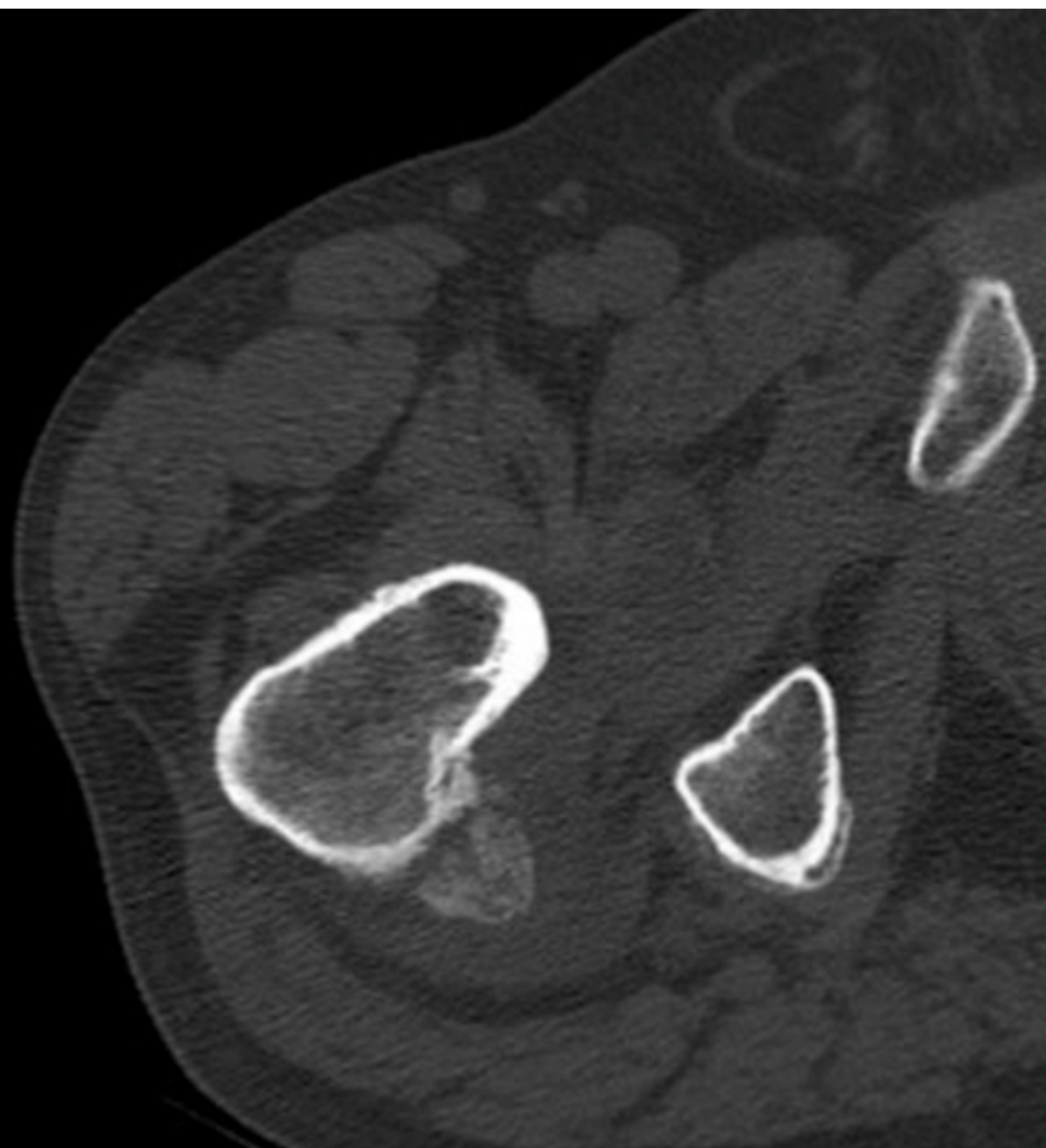
[gnielsen@partners.org](mailto:gnielsen@partners.org)



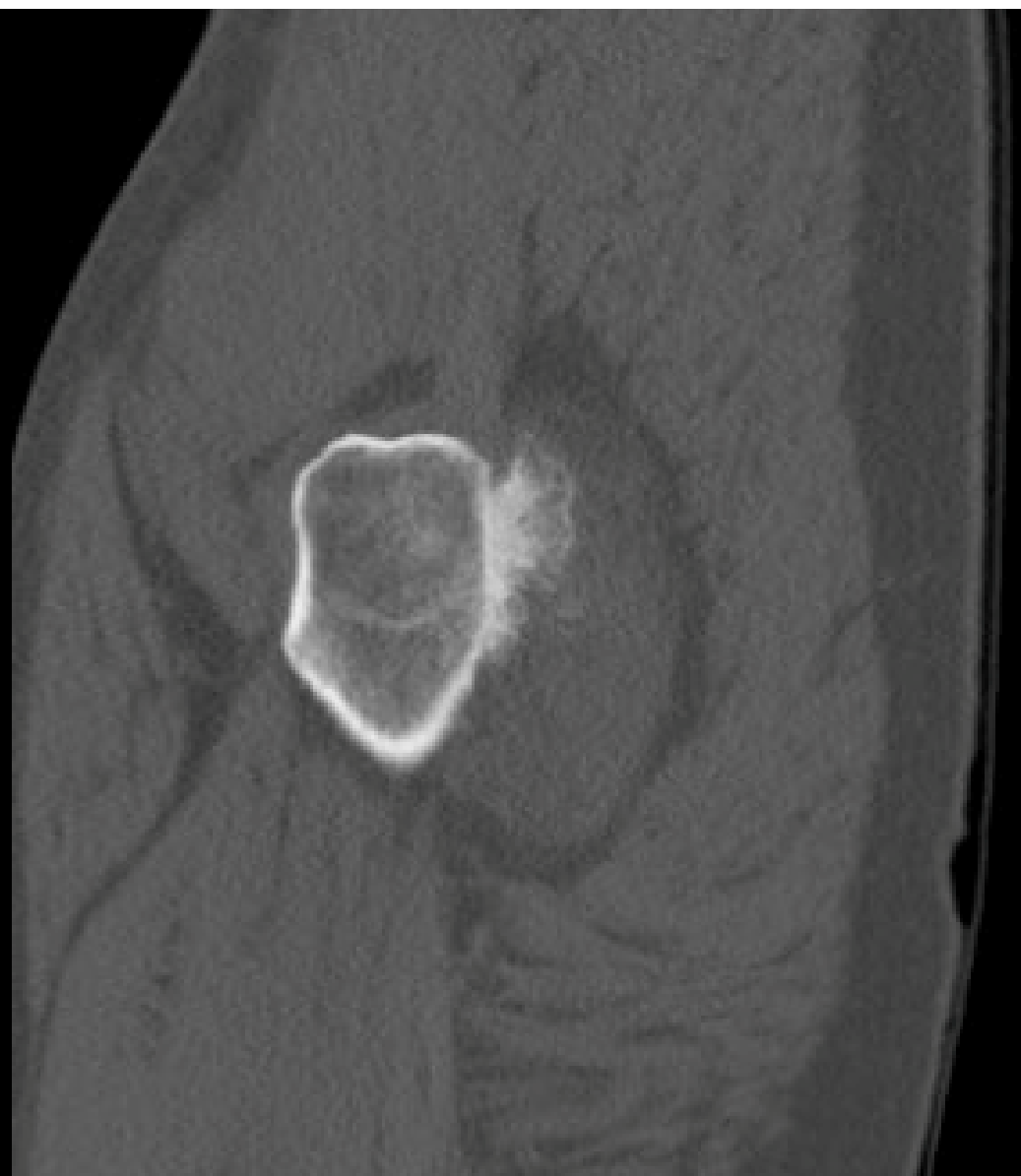
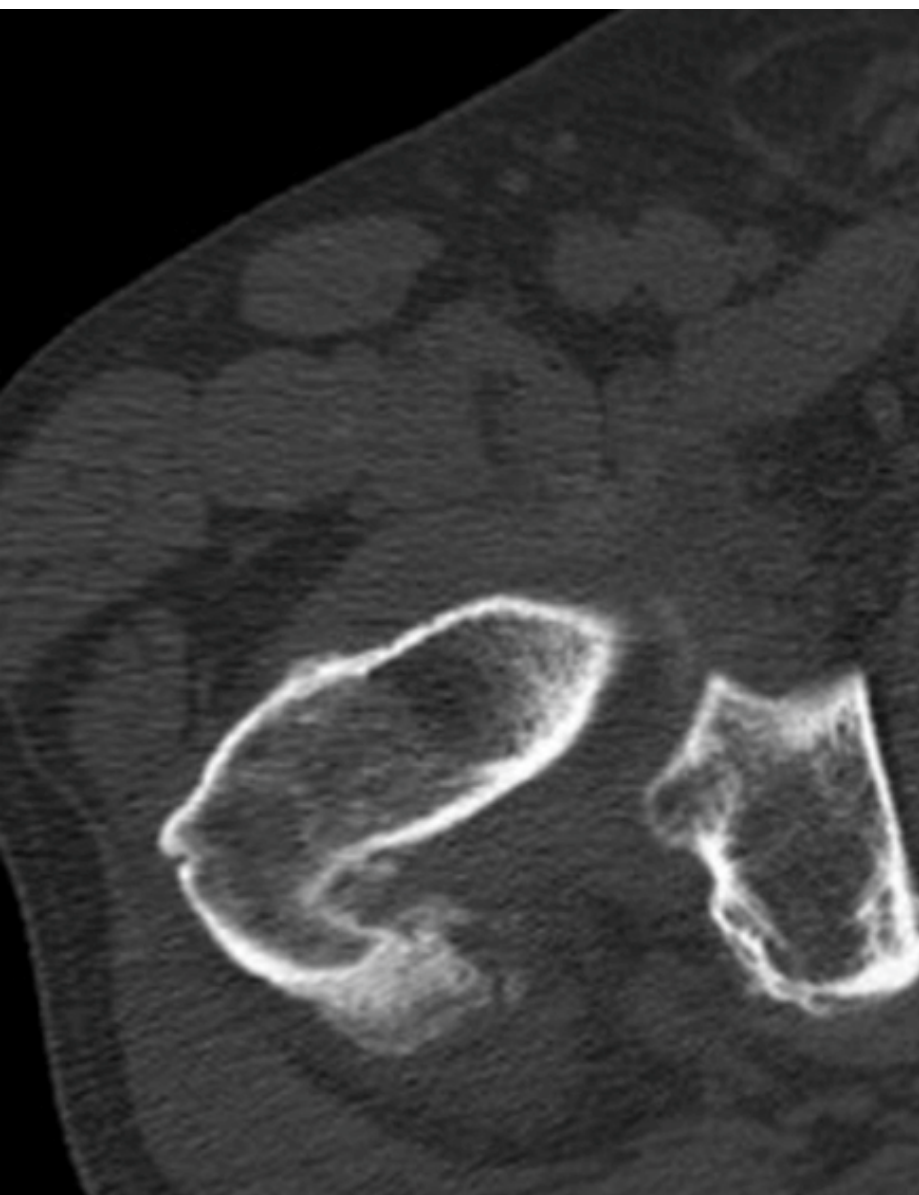
## CASE 6

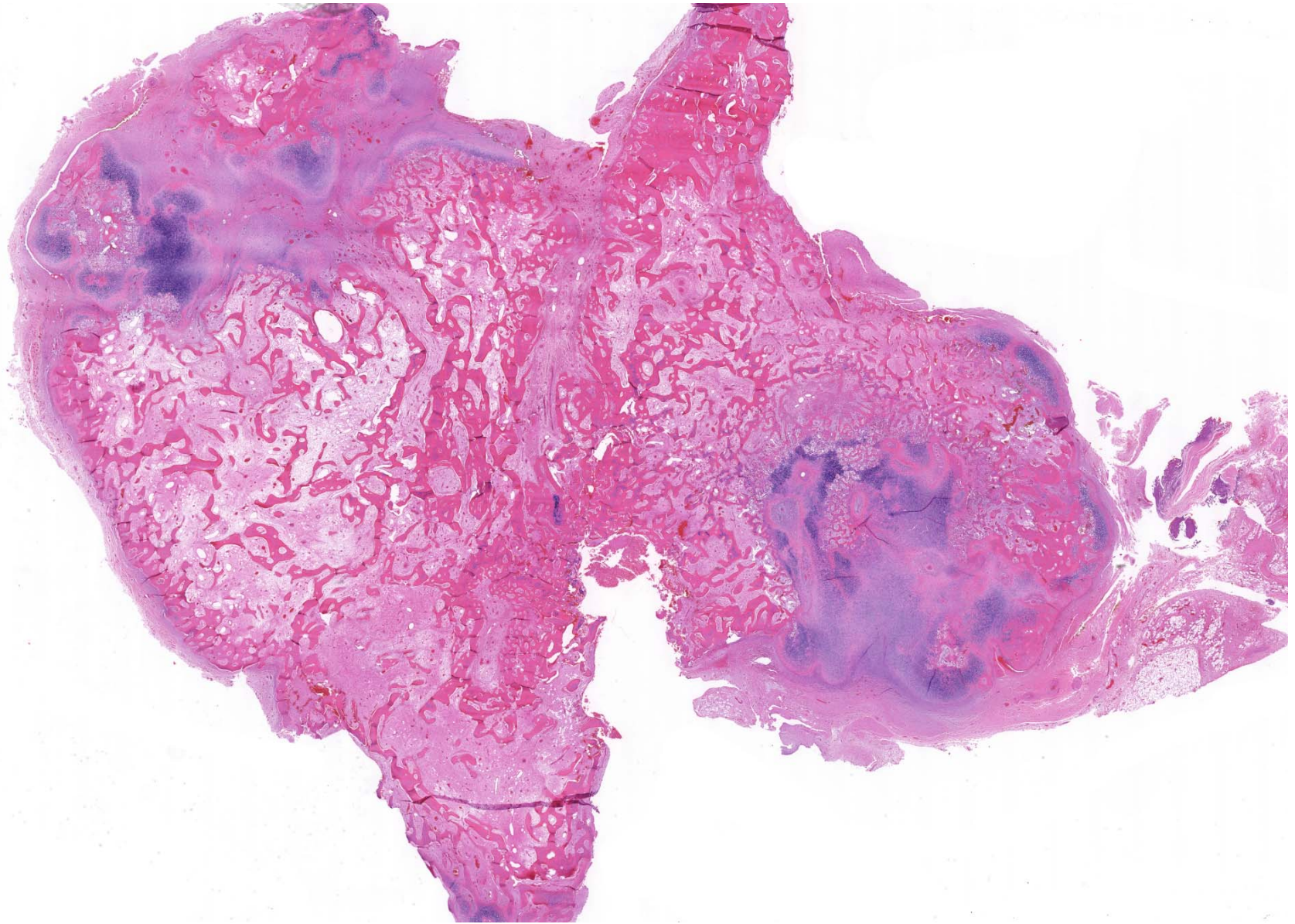
- 43 year old presented with pain in the right upper thigh that had recently increased. There was a history of minor trauma and injury in the remote past



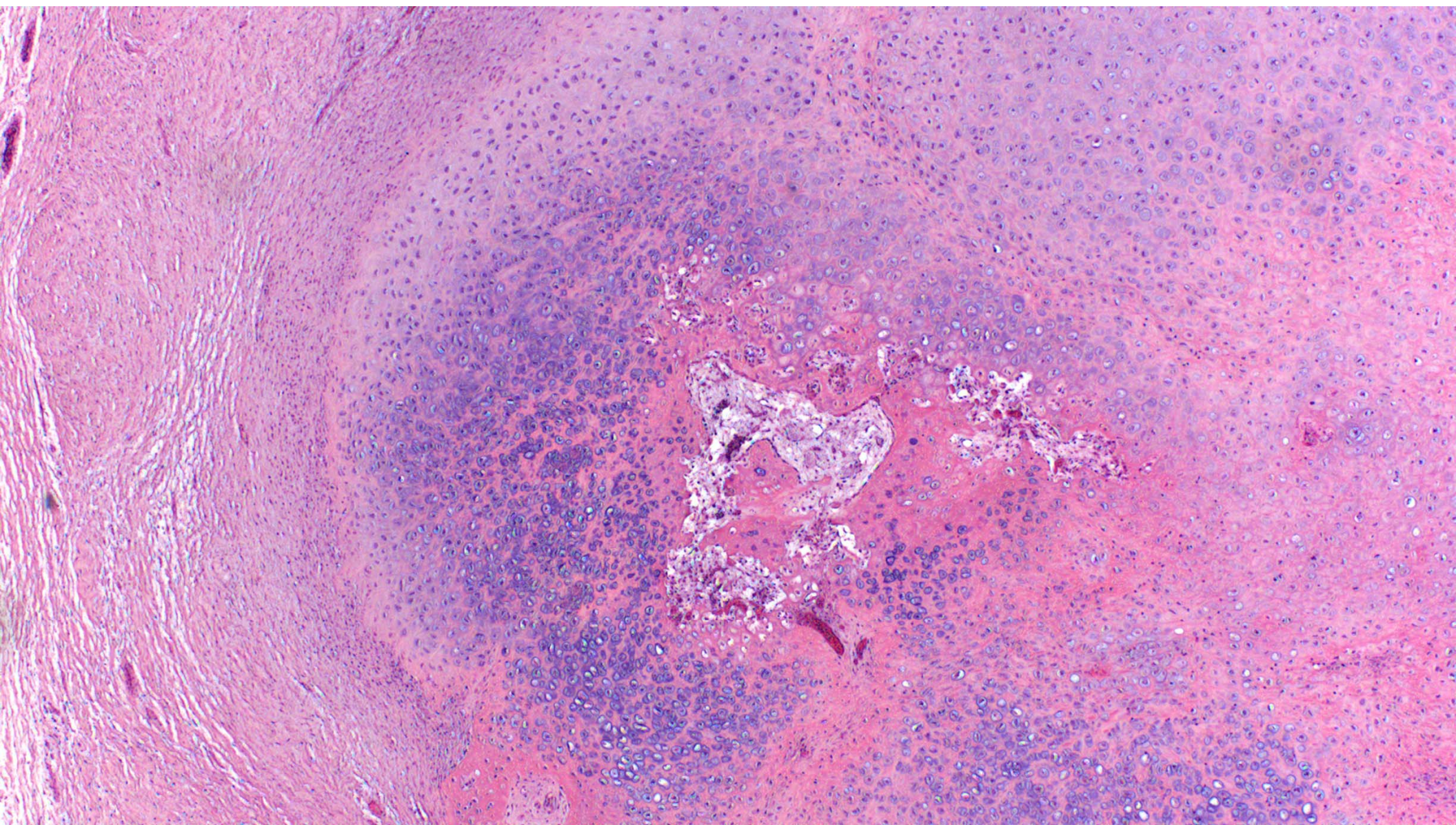




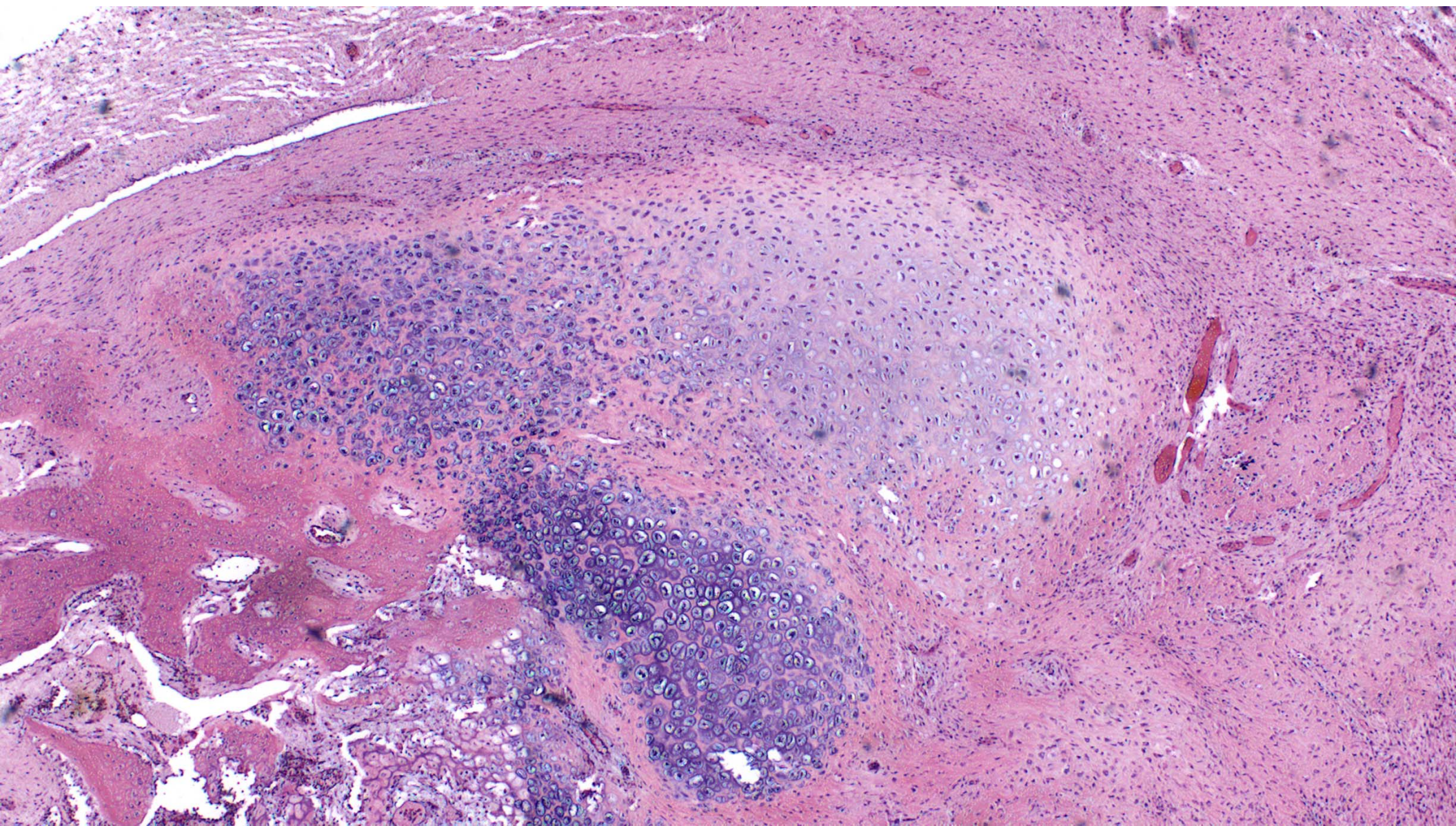




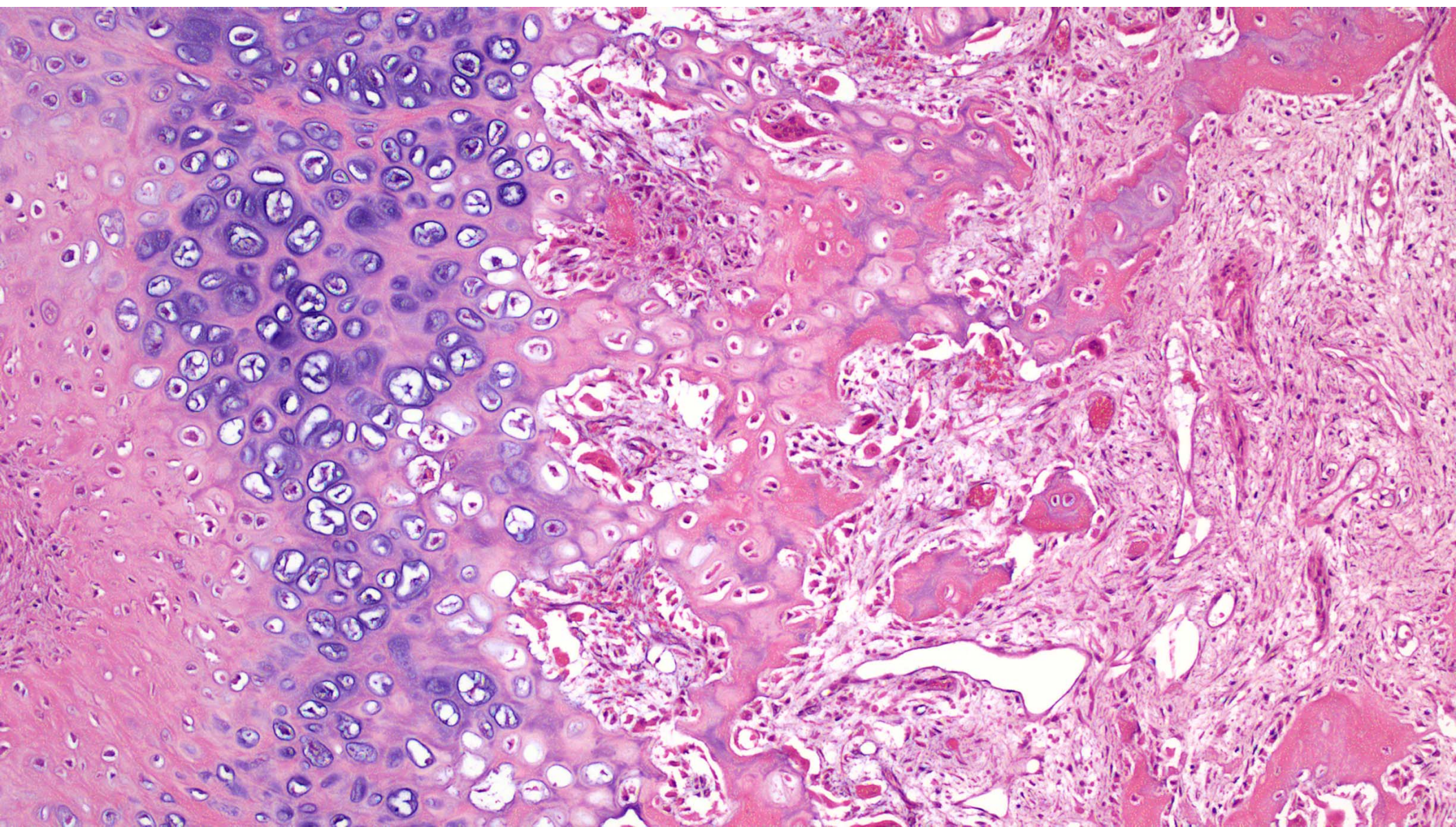
















## Diagnosis

Bizarre parosteal  
osteochondromatous proliferation  
(BPOP)



# BPOP

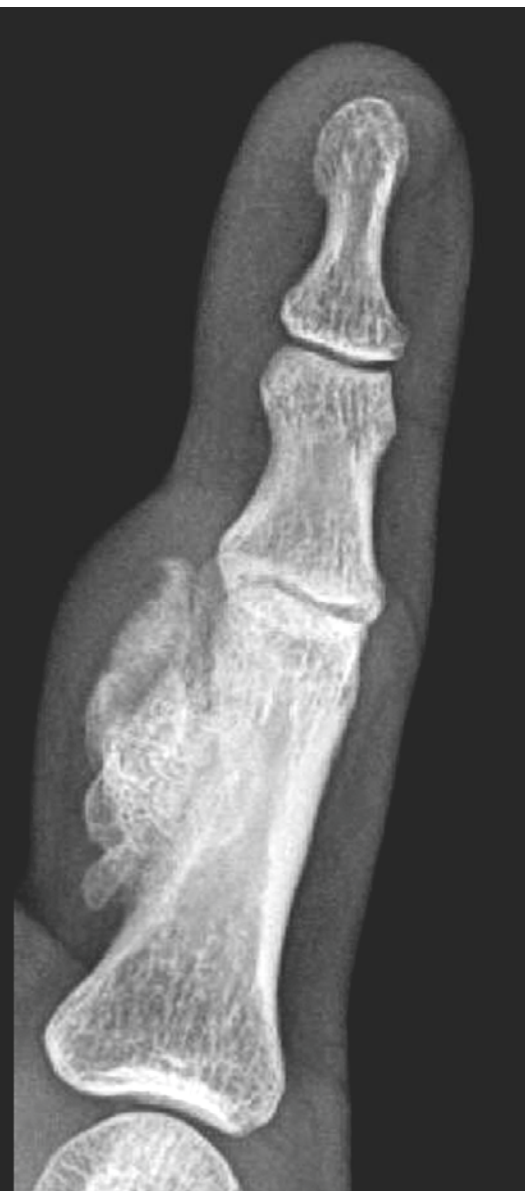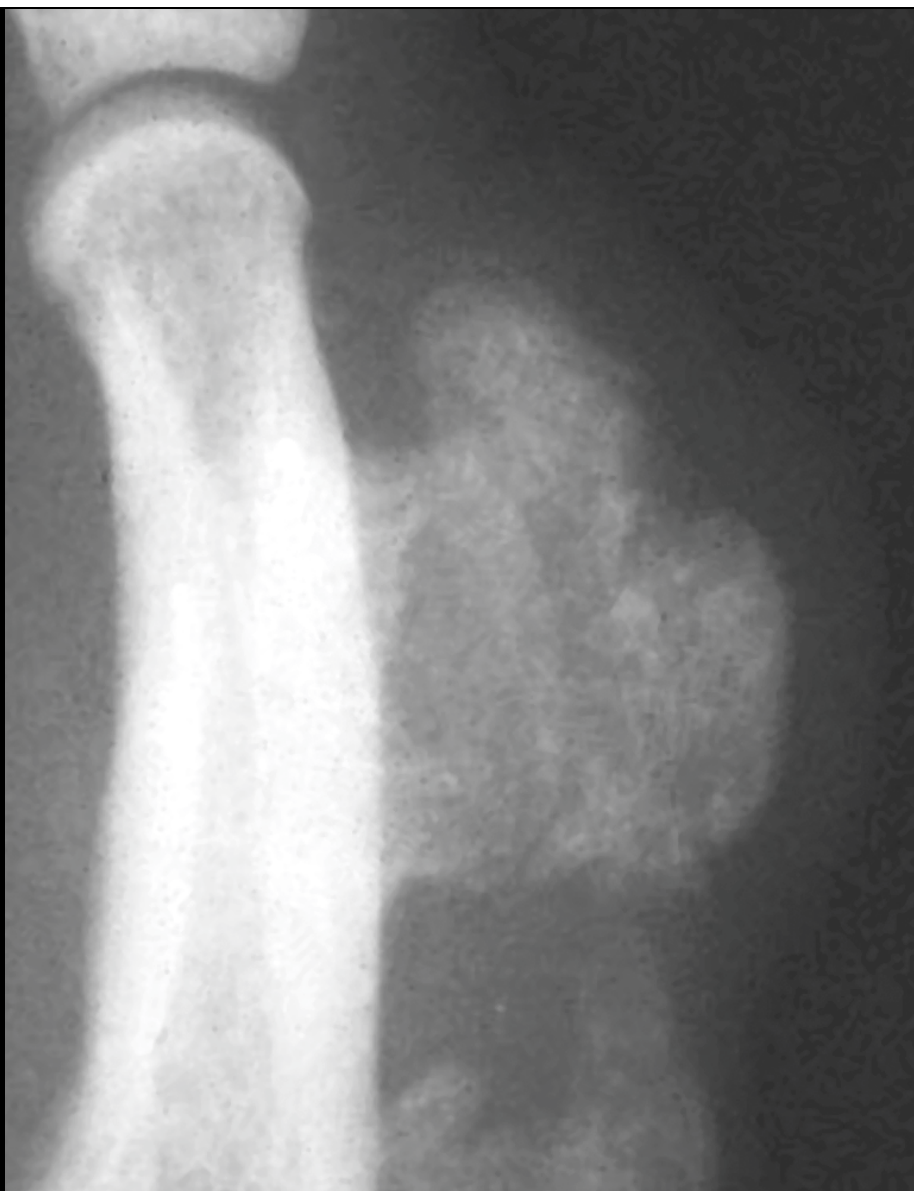- First described by Nora et al.
- 35 patients
- 14-74 years old
- 0.4-3 cm
- Proximal phalanges / metatarsals / metacarpals
- 18 local recurrence – 8 locally recurred twice
  - Nora et al. Bizarre parosteal osteochondromatous proliferations of the hands and feet. Am J Surg Pathol 1983; 7:245-250

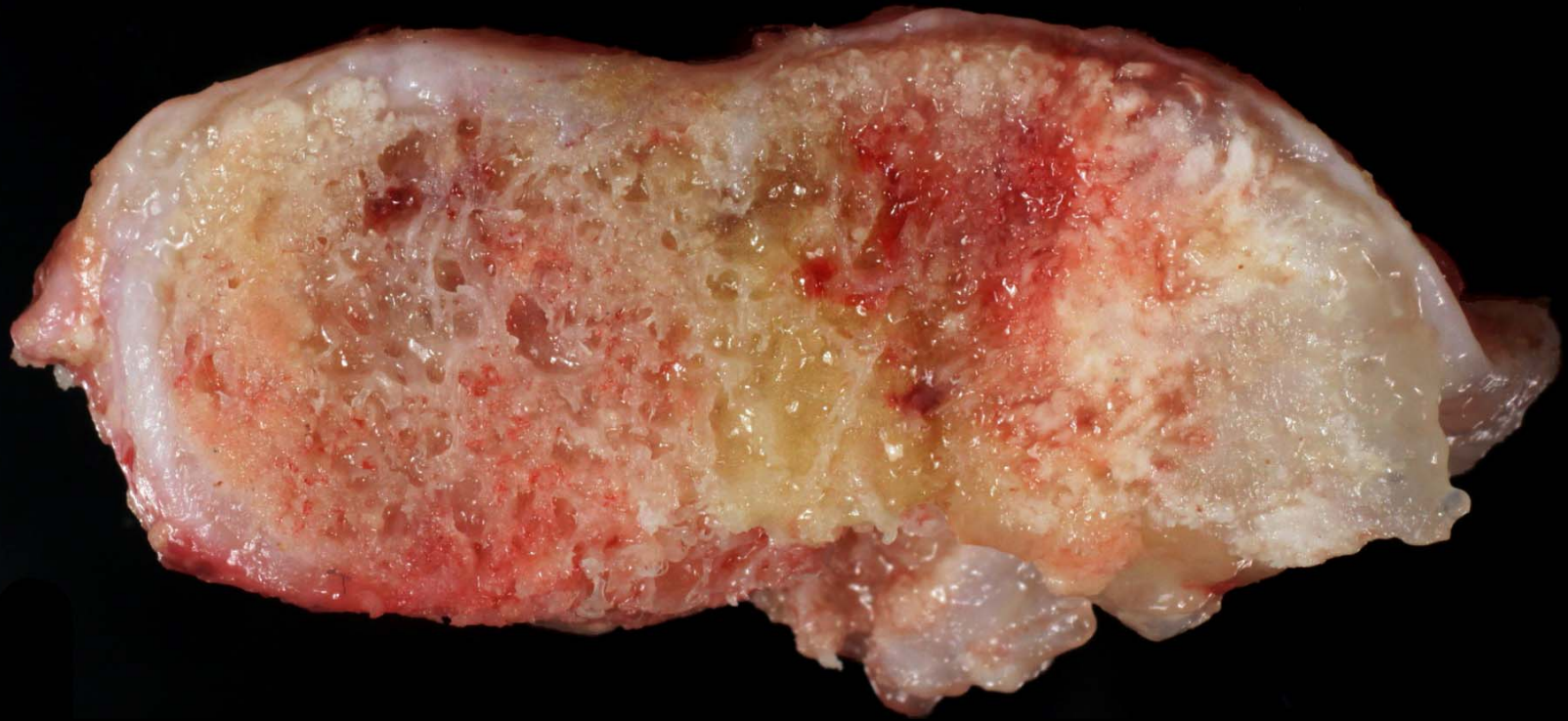


# BPOP

- 65 patients
  - 8-73 years old
  - 72% involved the **small bones**
  - 27% involved **long bones**
  - 14 with one local recurrence – 5 with two – 3 with three
- 
- Menses et al. Bizarre parosteal osteochondromatous proliferations of bone (Nora's lesion). Am J Surg Pathol 1993; 17:691-697



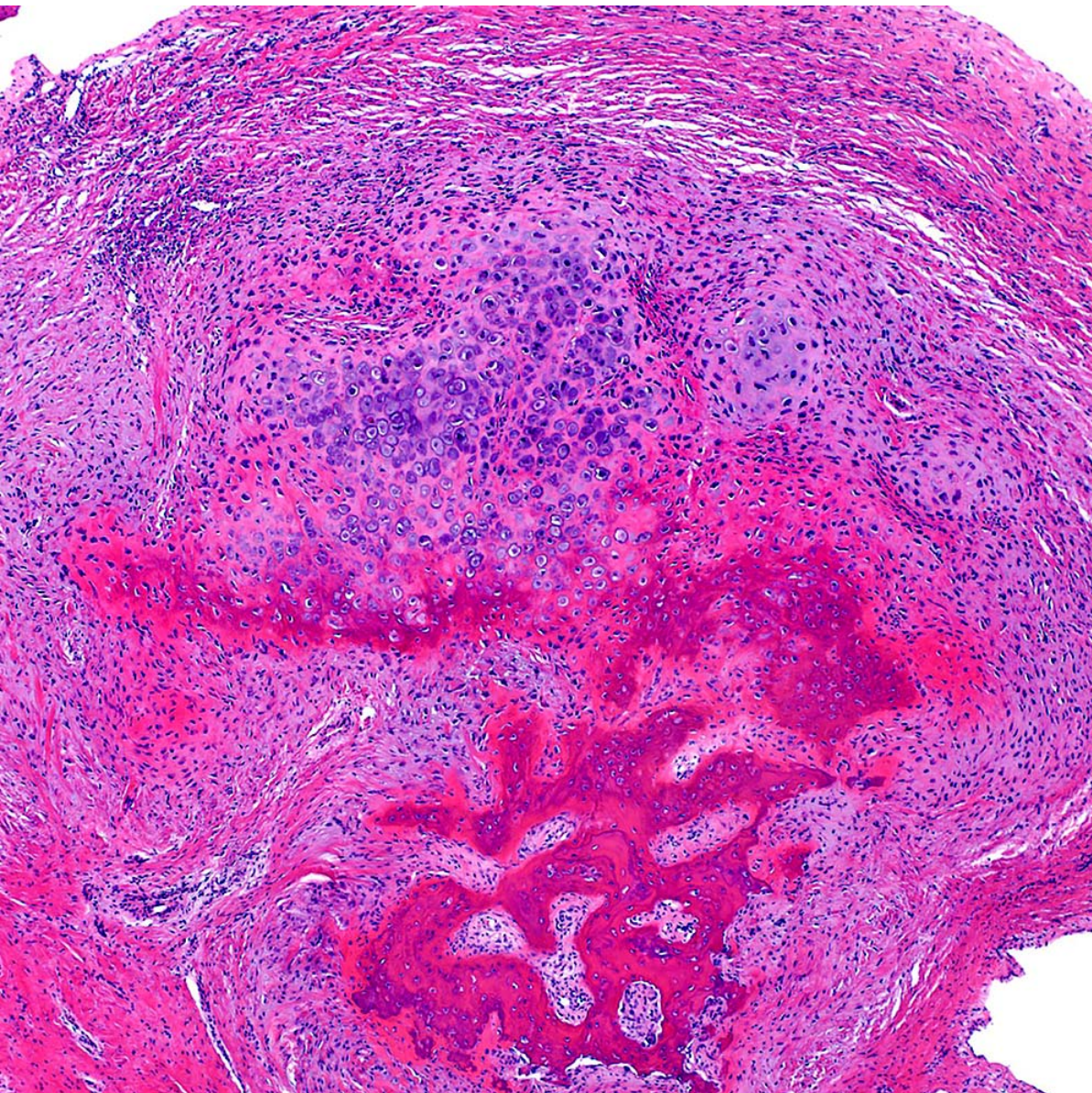




**Mass General Hospi**







Fibrous tissue

Cartilage

Bone



# BPOP

- Initially thought to be a non-neoplastic, reactive process
- **t(1;17(q32;q21))** has been identified supporting a neoplastic process
- Four cases with **inversion of chromosome 7** have been described

- Nilsson et al et al. Molecular cytogenetic characterization of recurrent translocation breakpoints in bizarre parosteal osteochondromatous proliferation (Nora's lesion). *Human Pathology* 2004;35:1063-1069
- Endo et al. Bizarre parosteal osteochondromatous proliferation with a t(1;17) translocation. *Virchows Archiv* 2005;447:99-102
- Broehm et al. Bizarre parosteal osteochondromatous proliferation: a new cytogenetic subgroup characterized by inversion of chromosome 7. *Cancer Genetics* 2013;206:402-405



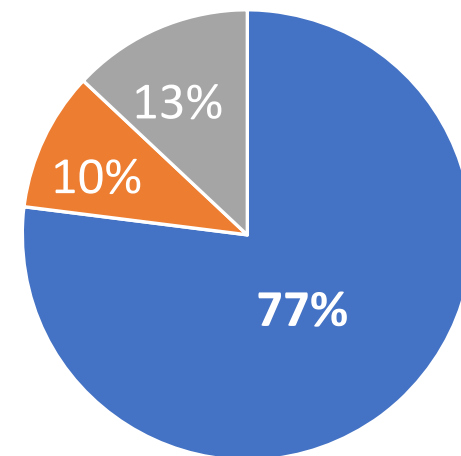
## BPOP – Differential Diagnosis

- **Small bones**
  - Subungual exostosis
  - Florid reactive periostitis

# Subungual Exostosis

- Arises in a subungual location
- **t(X;6)(q24-26;q15-21)**

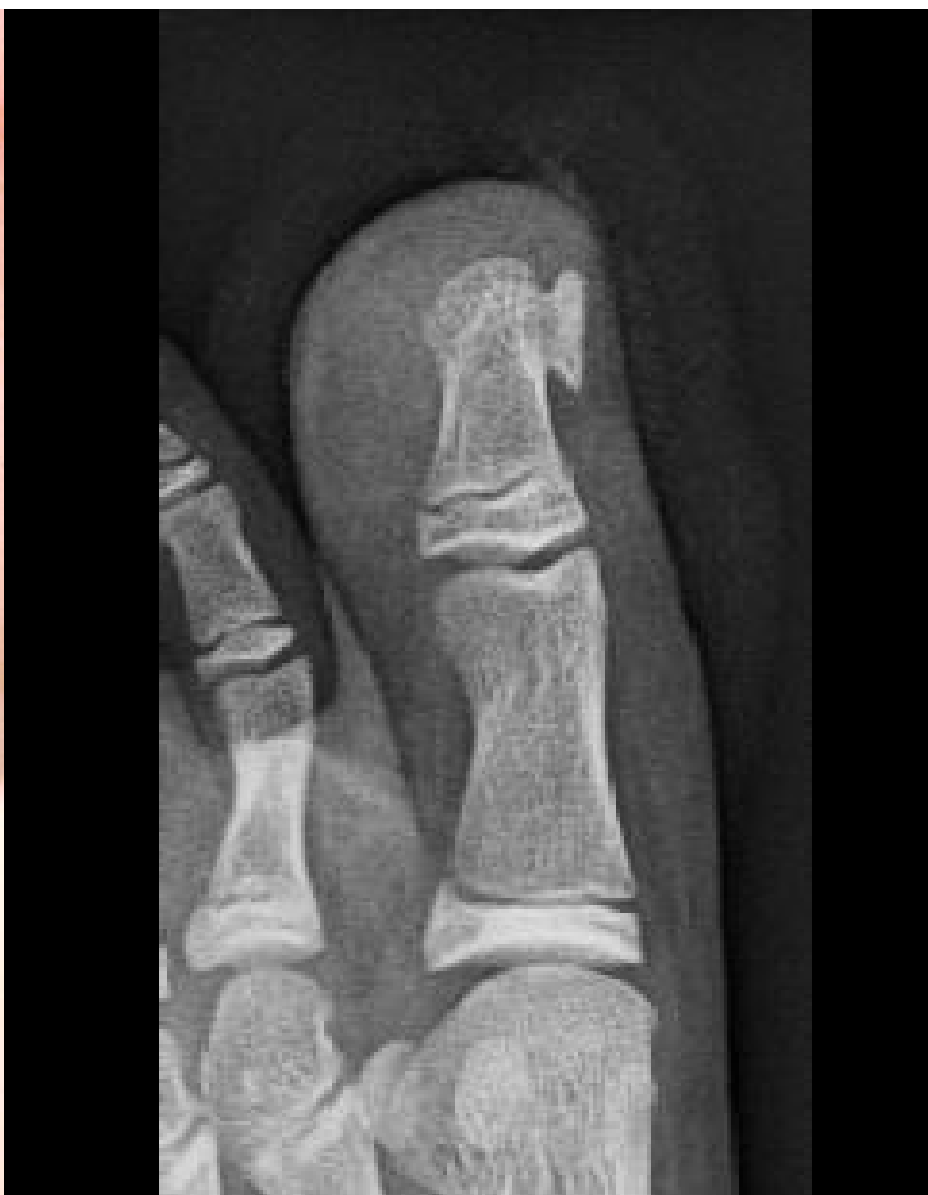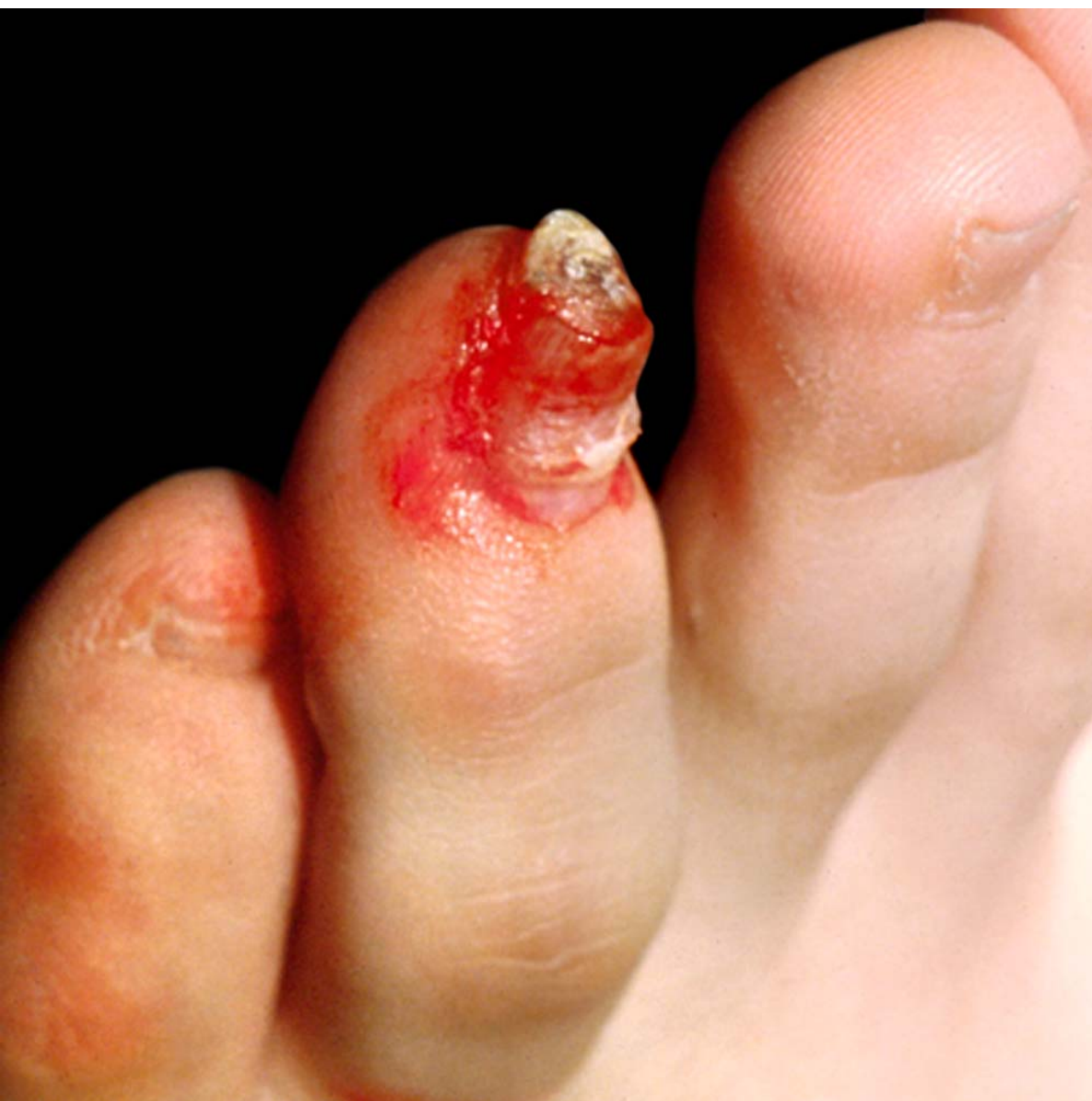Location of Subungual Exostosis  
Based on 244 Cases

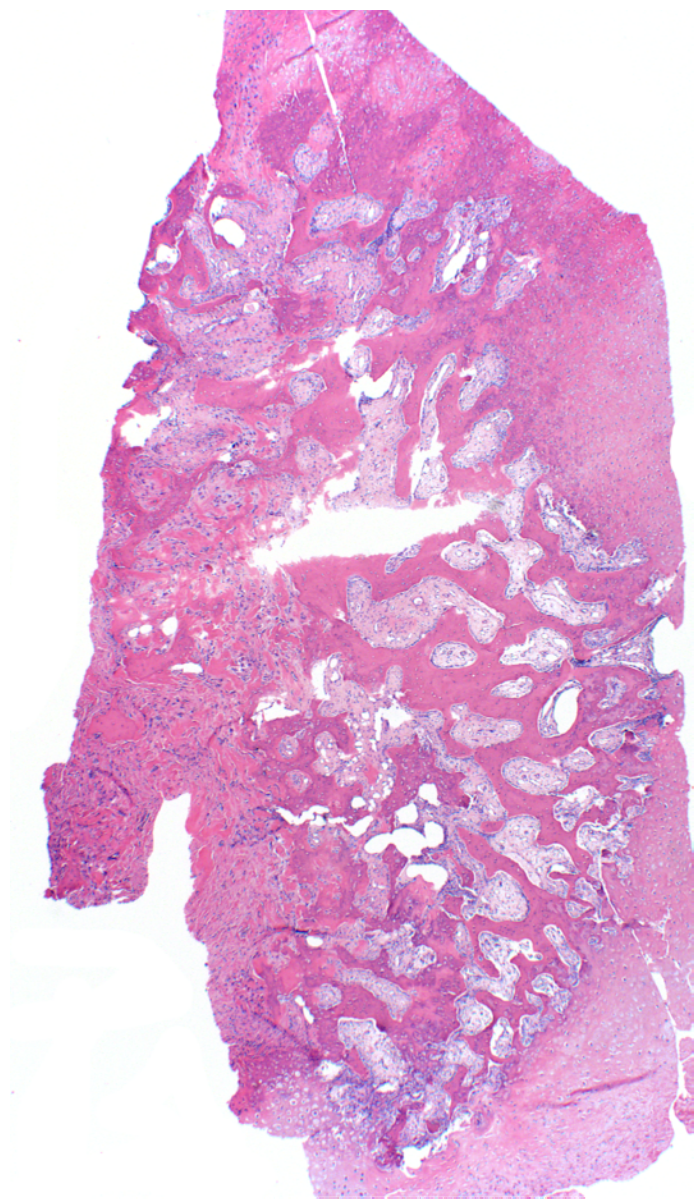
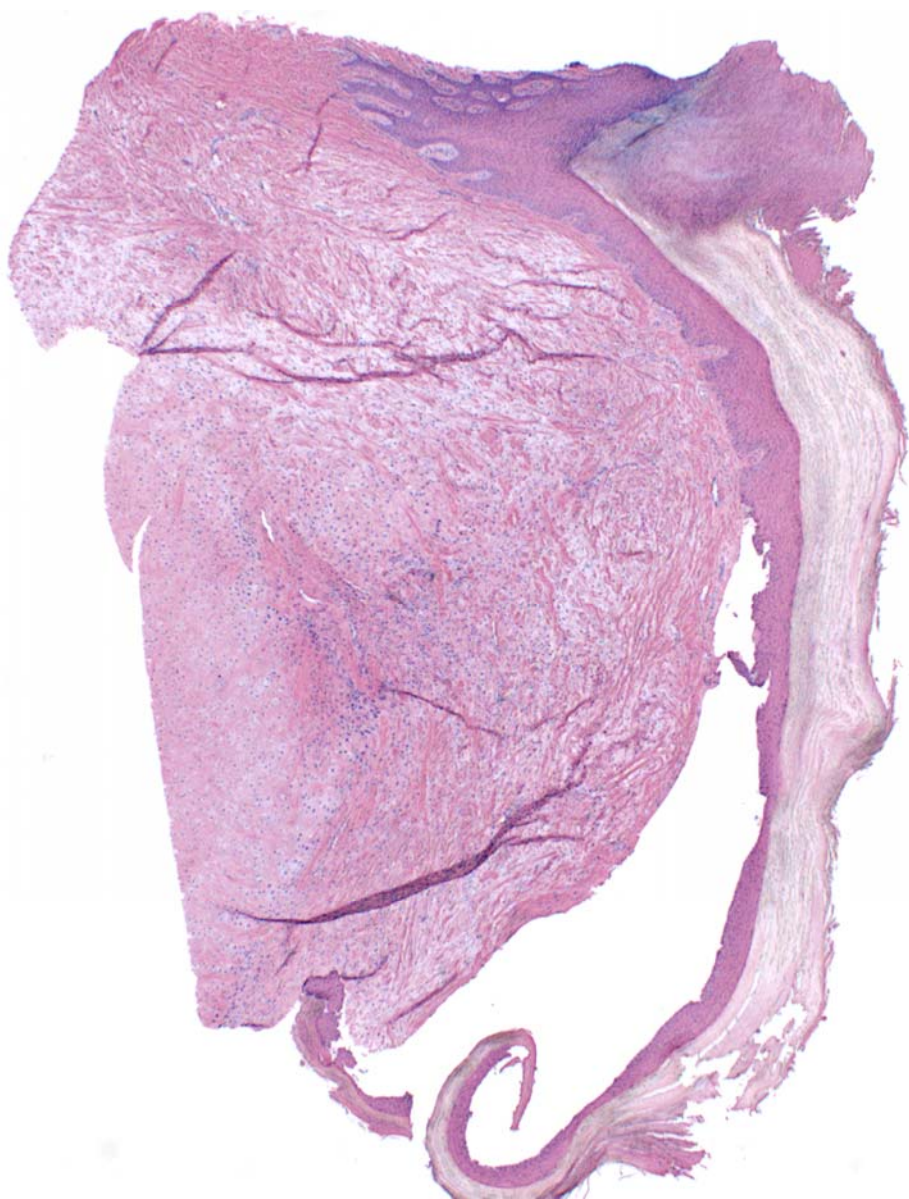


■ Great Toe ■ Other Toes ■ Fingers

- DaCabra et al. Subungual Exostosis of the Toes: A Systematic Review. Clin Orthop Relat Res 2014;472:1251-1259
- Mertens et al. The t(X;6) in subungual exostosis results in transcriptional deregulation of the gene for insulin receptor substrate 4. Int. J. Cancer 2011;128:487-491







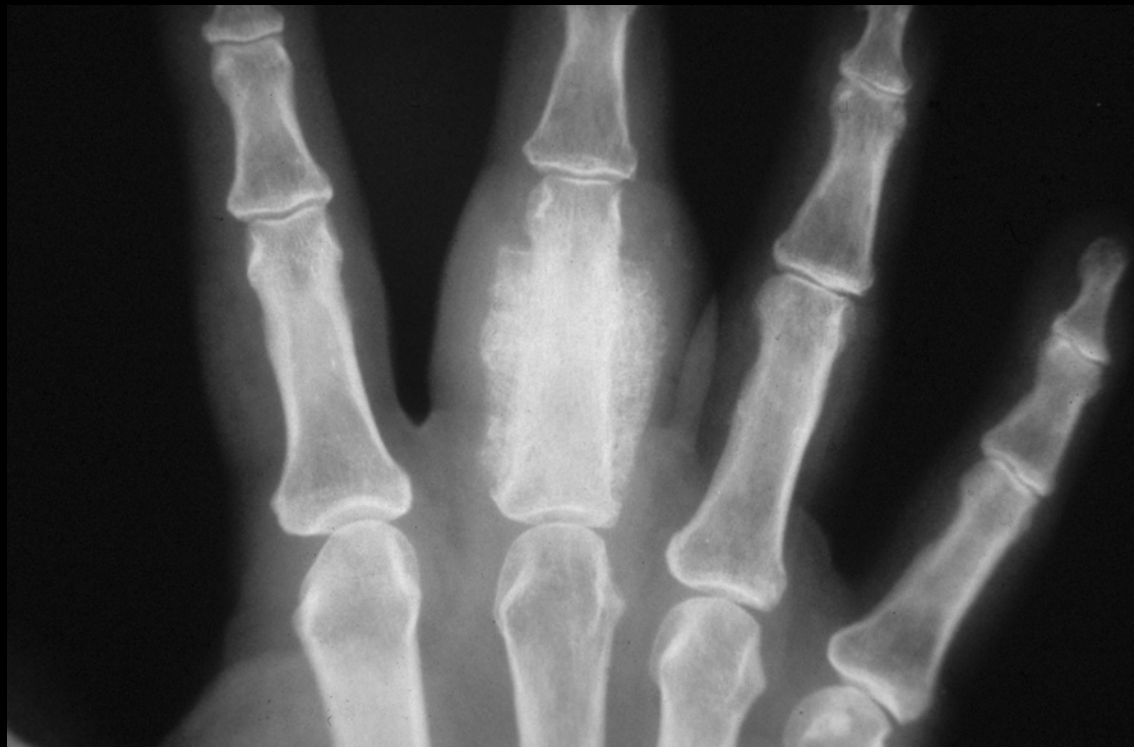
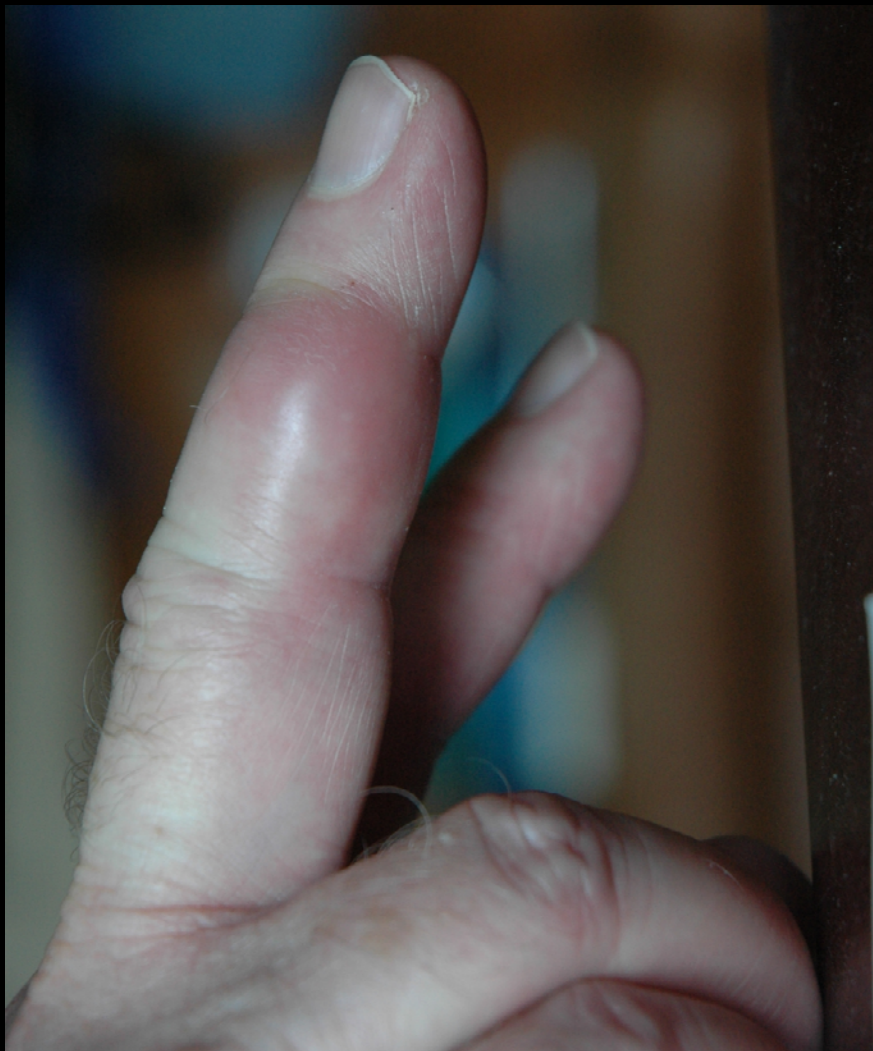


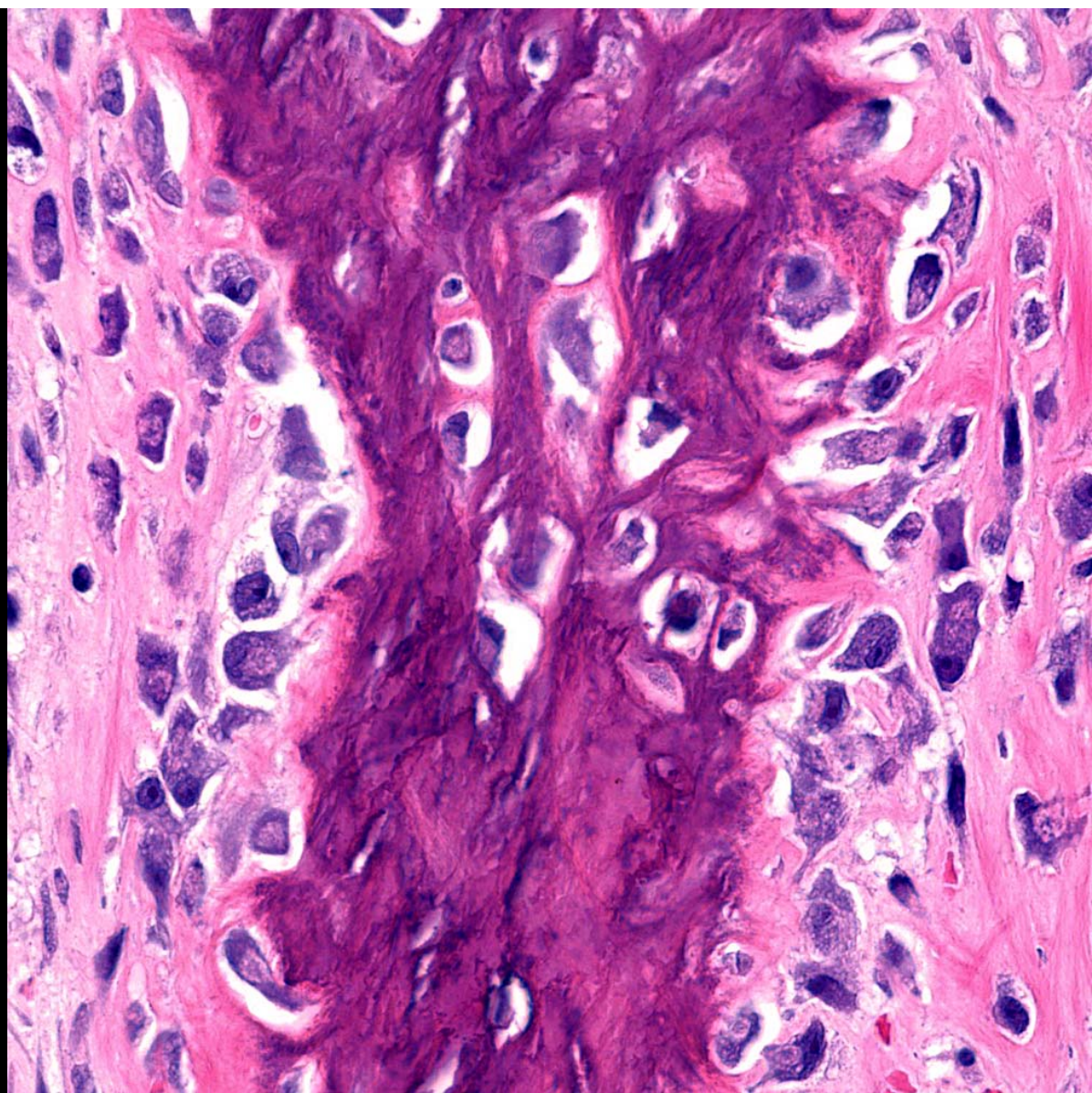
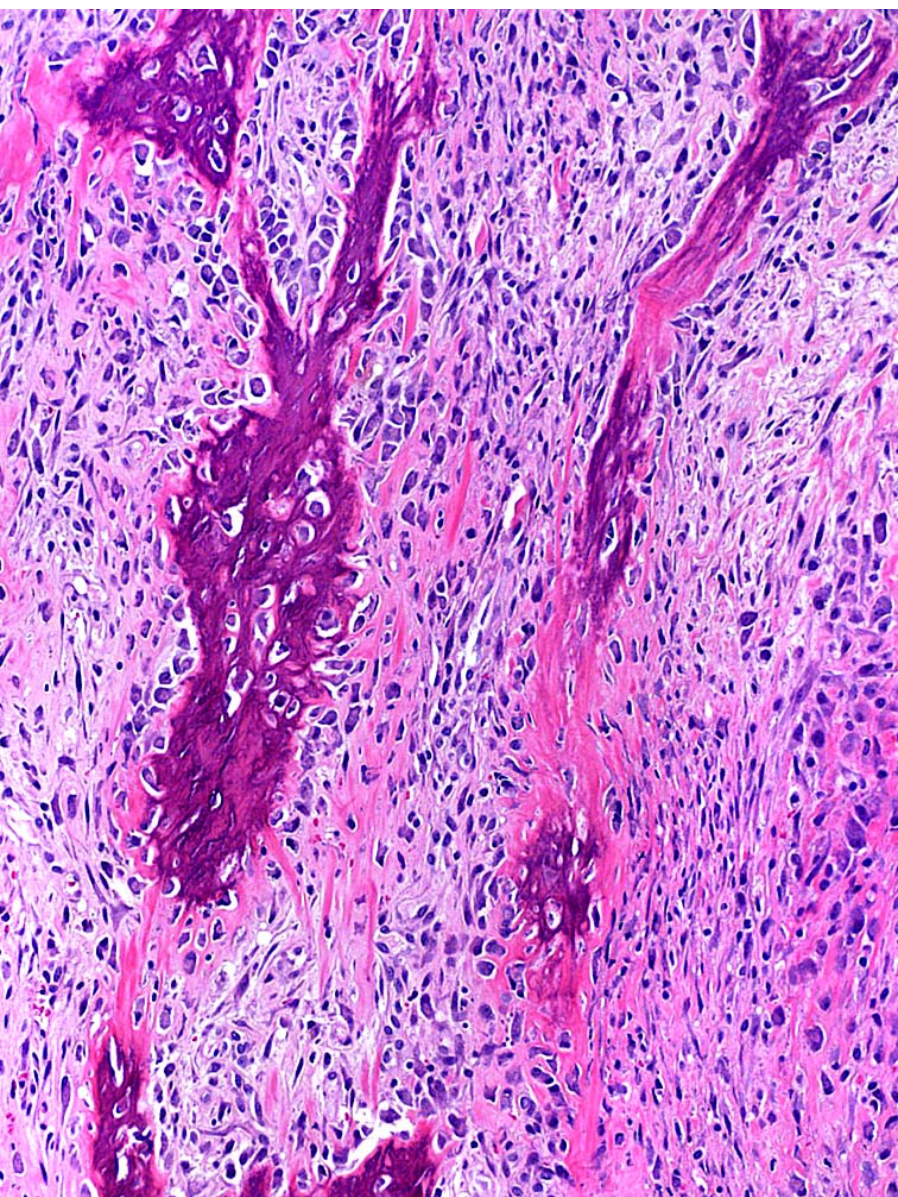
## Florid Reactive Periostitis

- Surface lesion of small bones of hands and feet (parosteal fasciitis – unusual myositis ossificans)
- Probably reactive / traumatic process – no genetic abnormality has been identified

■ Spjut et al. Florid reactive periostitis of the tubular bones of the hands and feet. A benign lesion which may simulate osteosarcoma. *Am J Surg Pathol* 1981;5:423-433







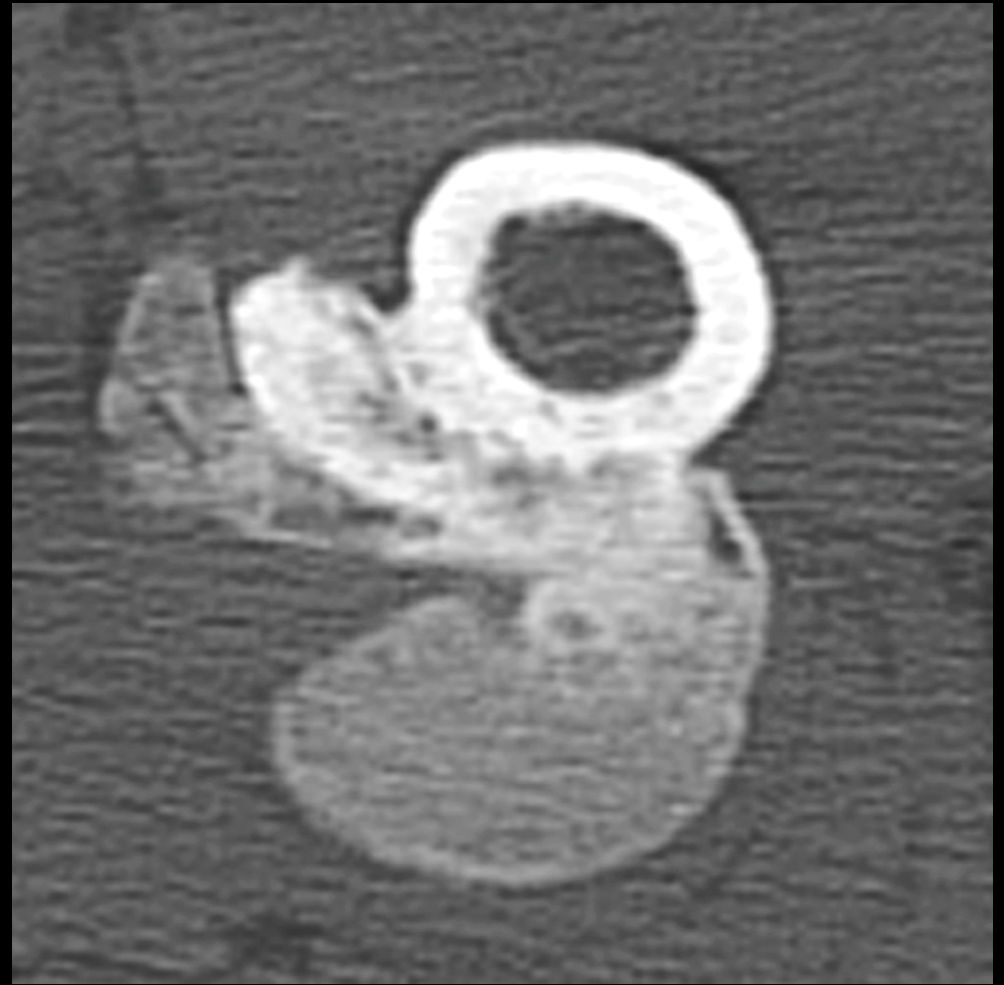
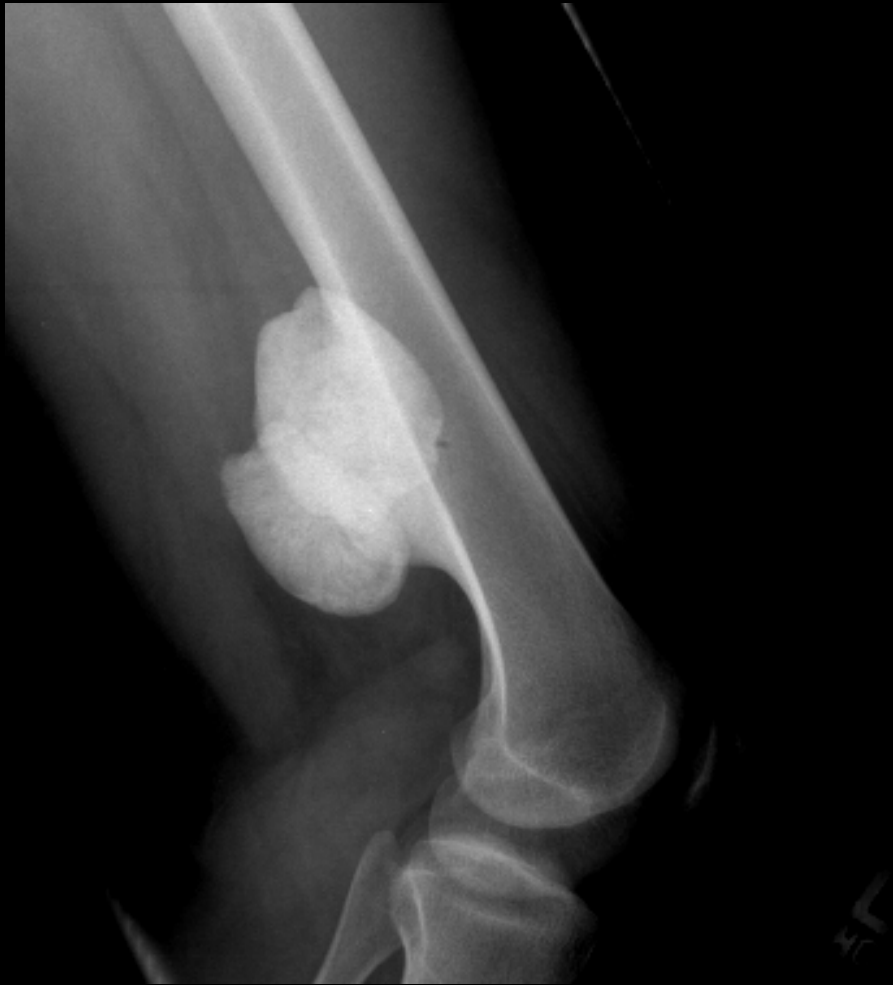


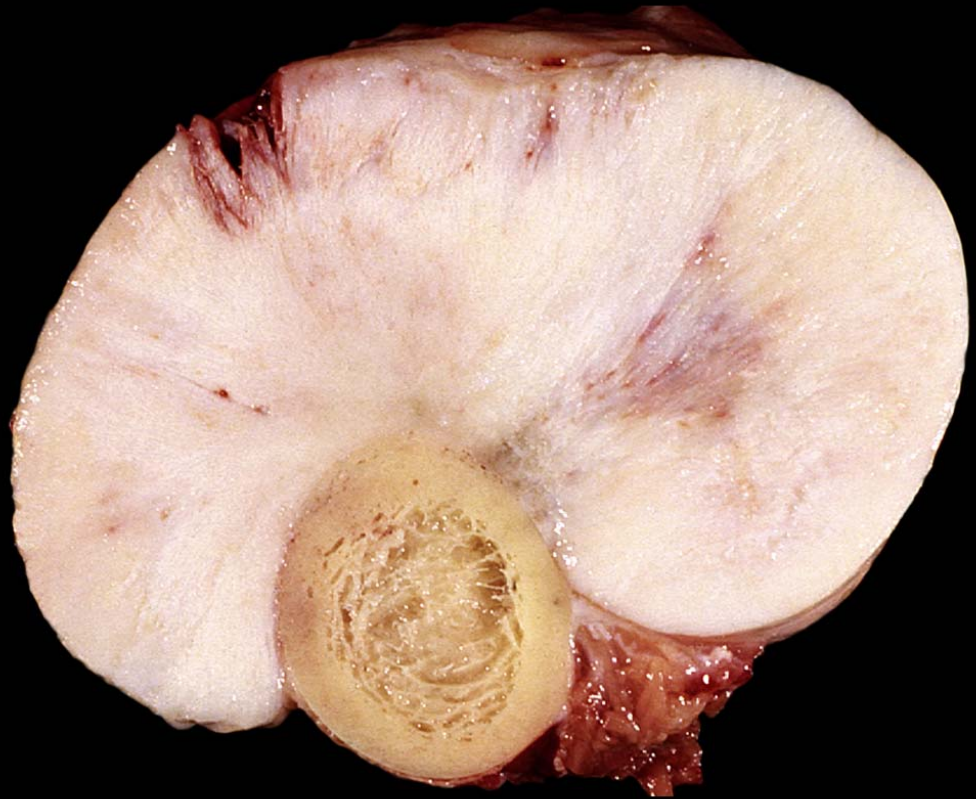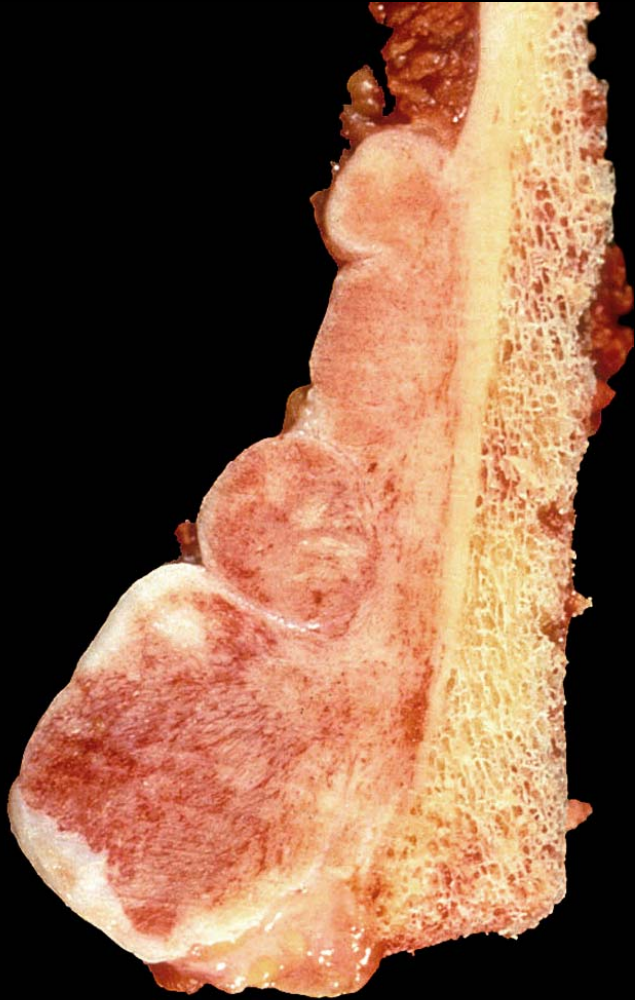## BPOP – Differential Diagnosis

- Long bones
  - Parosteal osteosarcoma
  - Periosteal osteosarcoma
  - Osteochondroma

# Parosteal Osteosarcoma

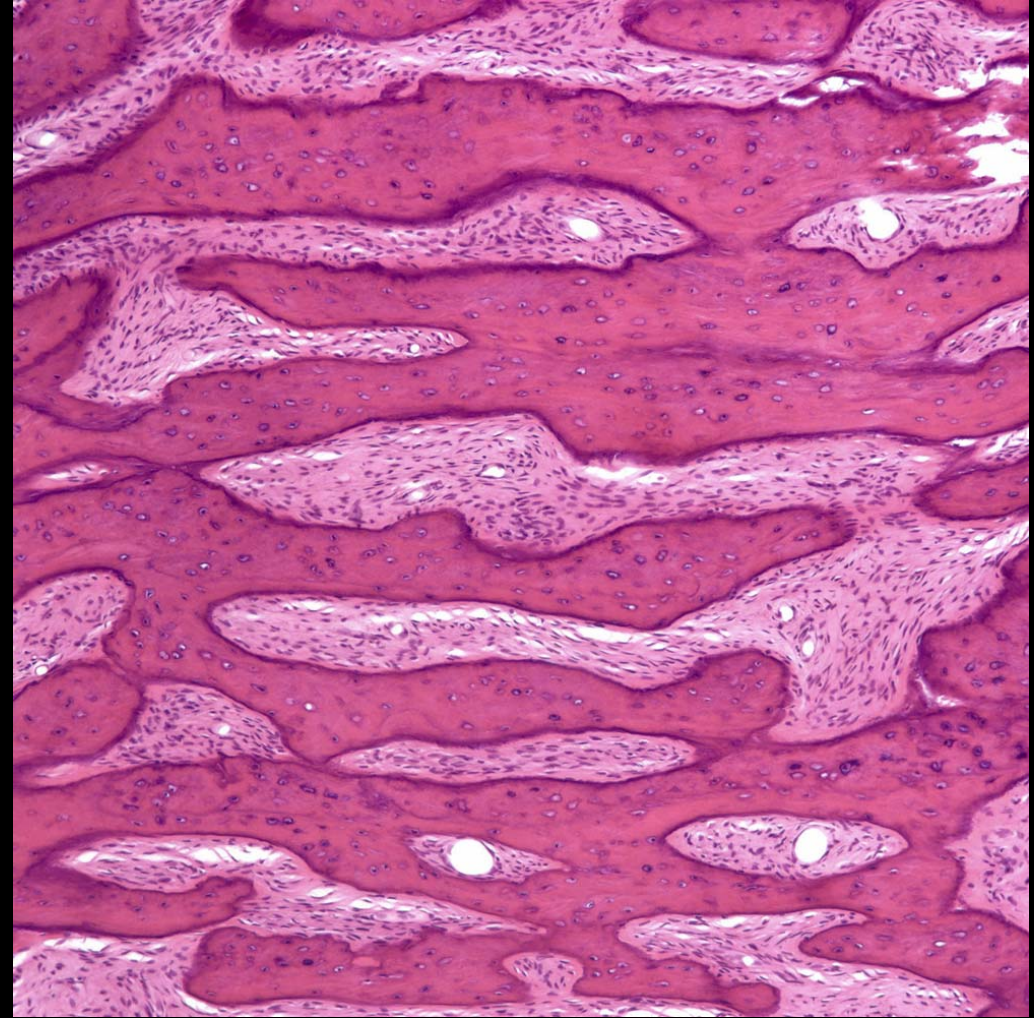
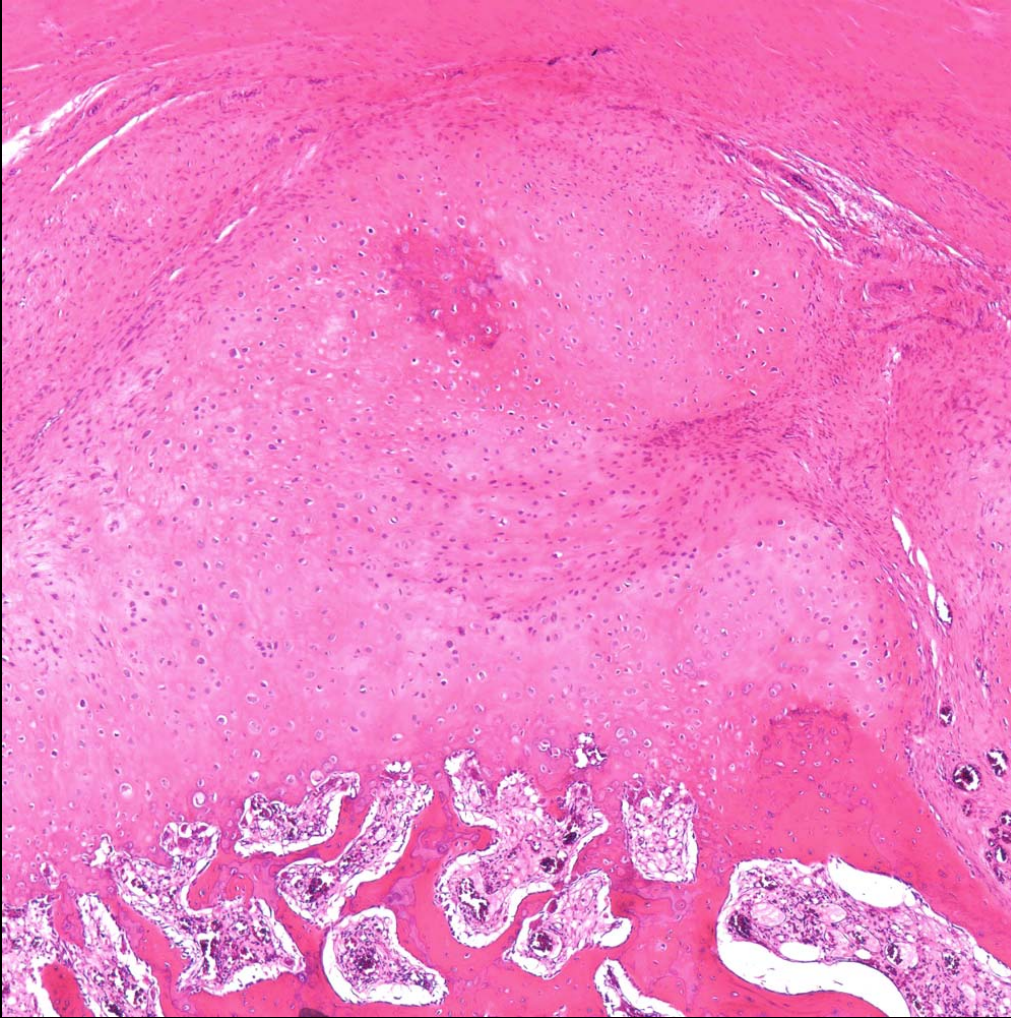


# Parosteal Osteosarcoma



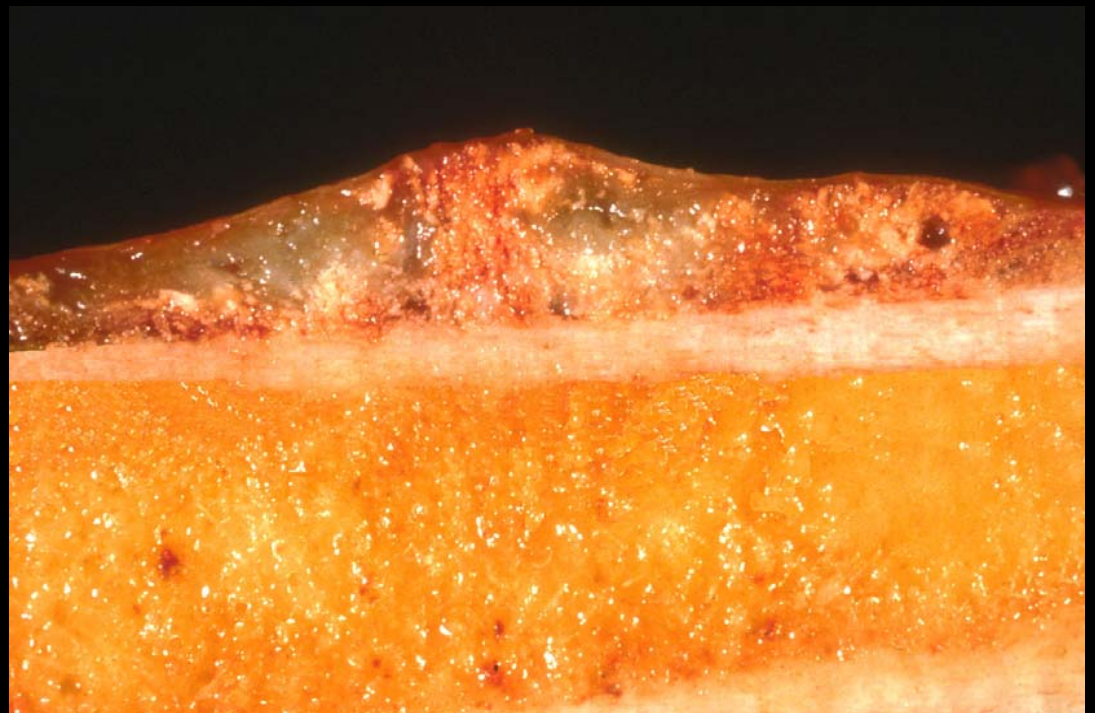
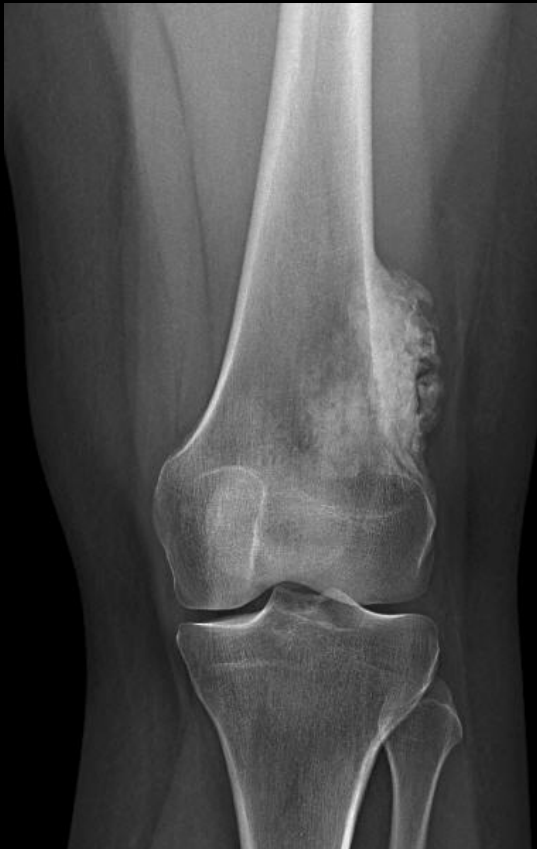

# Parosteal Osteosarcoma



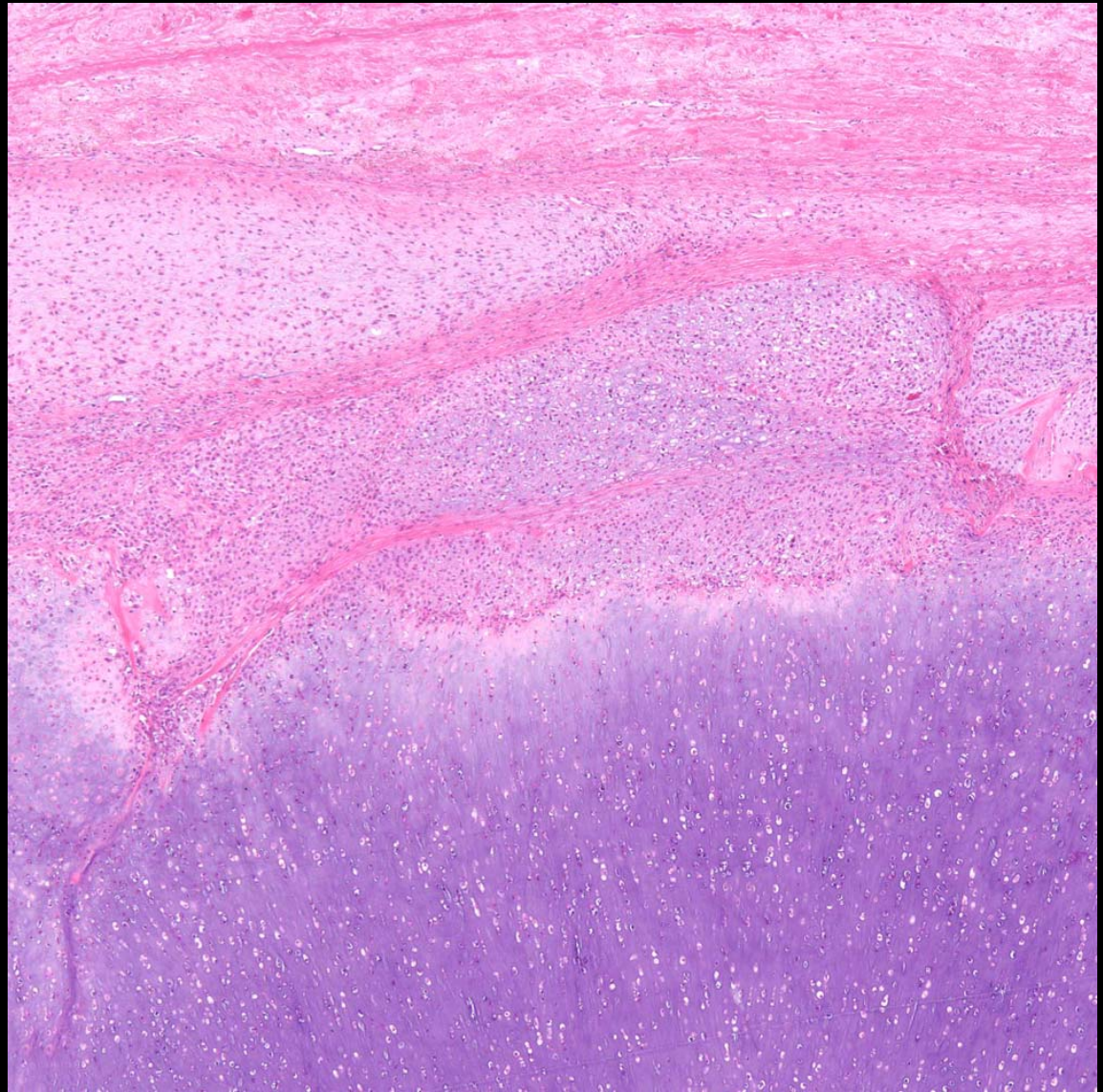


# Periosteal Osteosarcoma

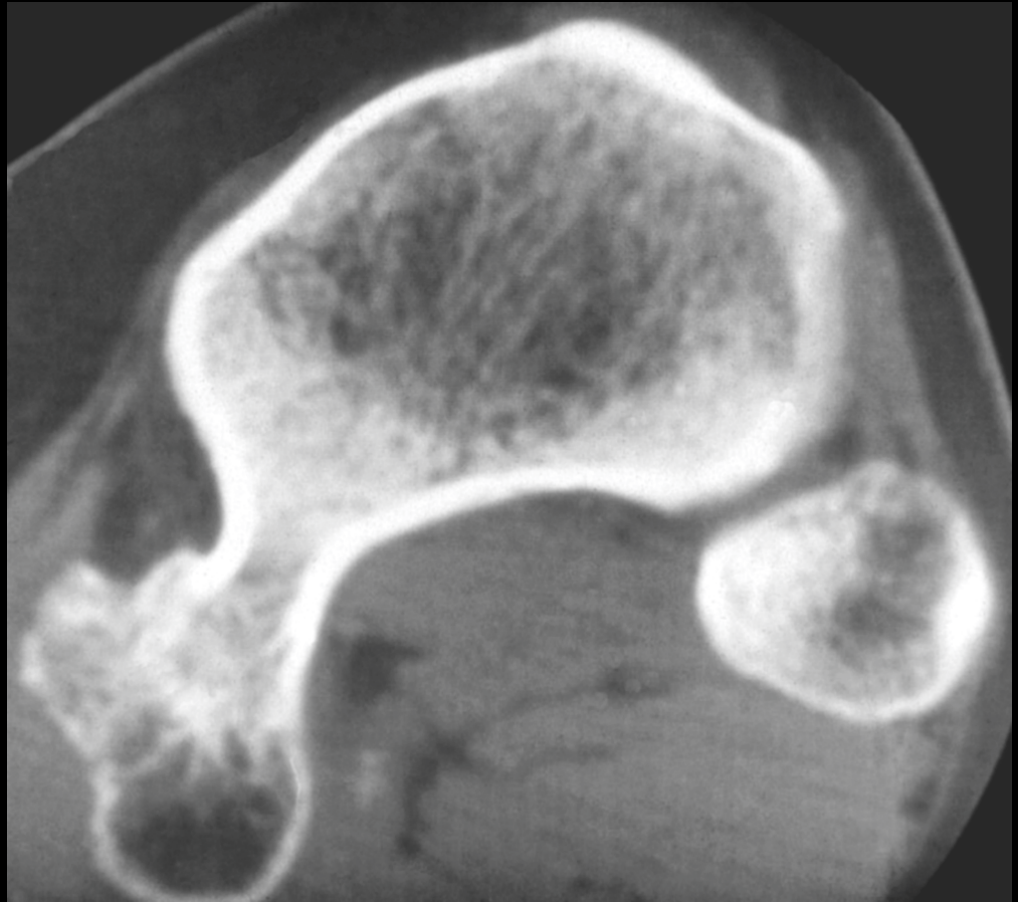
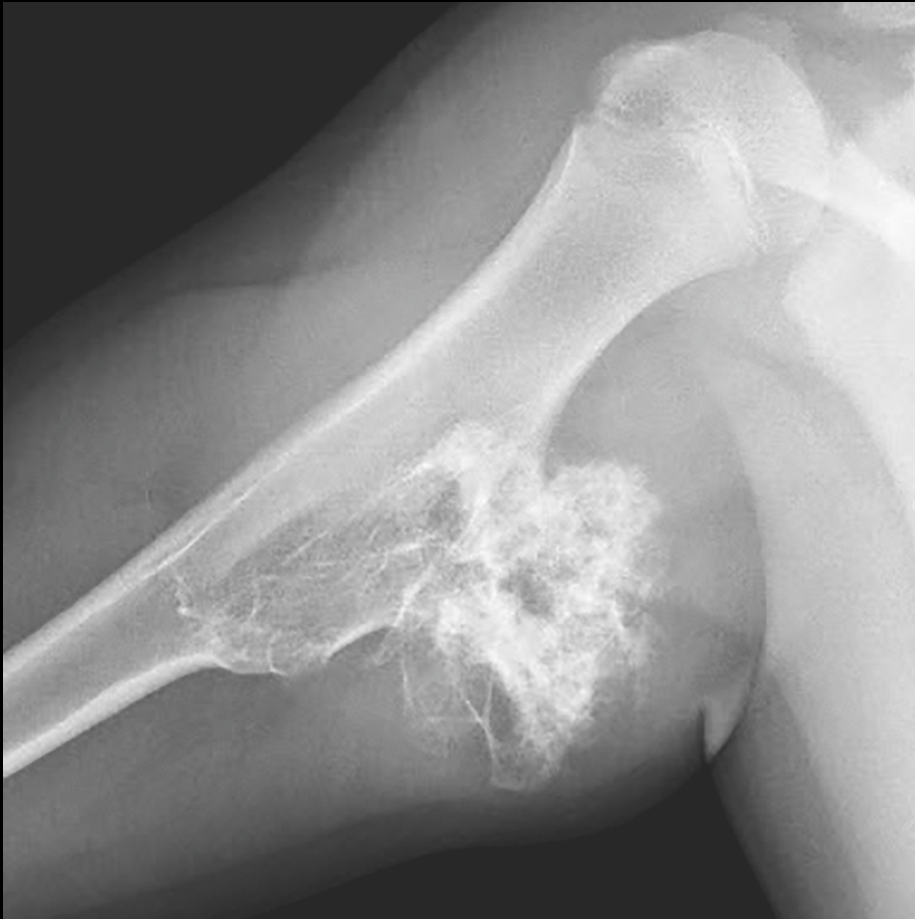



# Periosteal Osteosarcoma

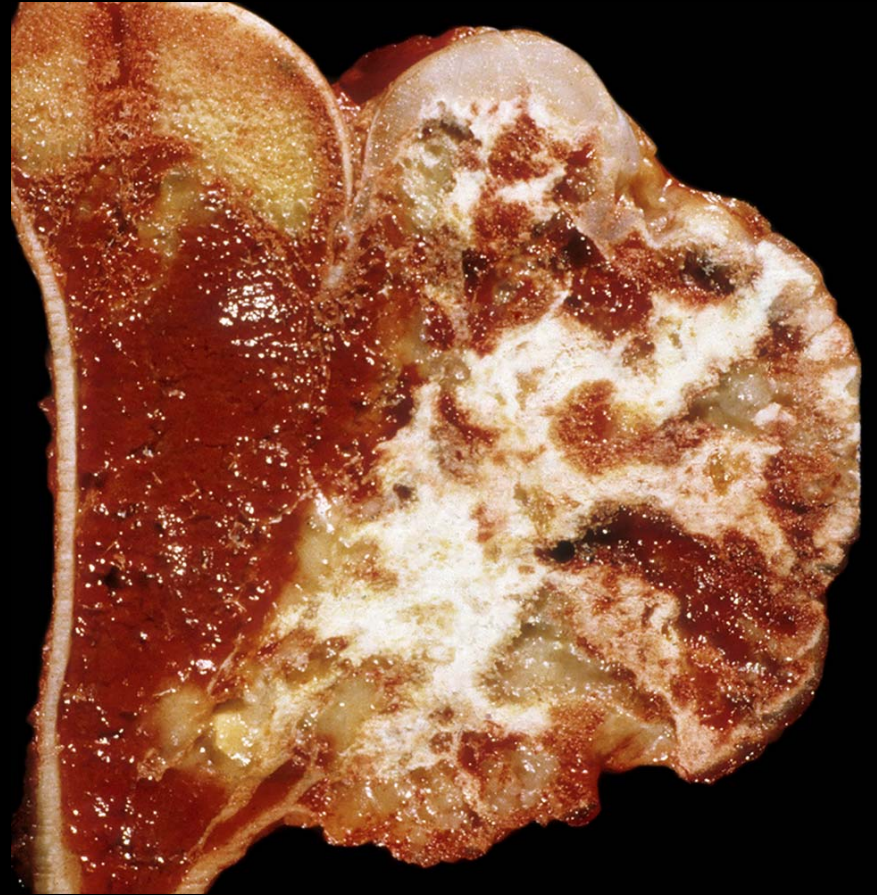
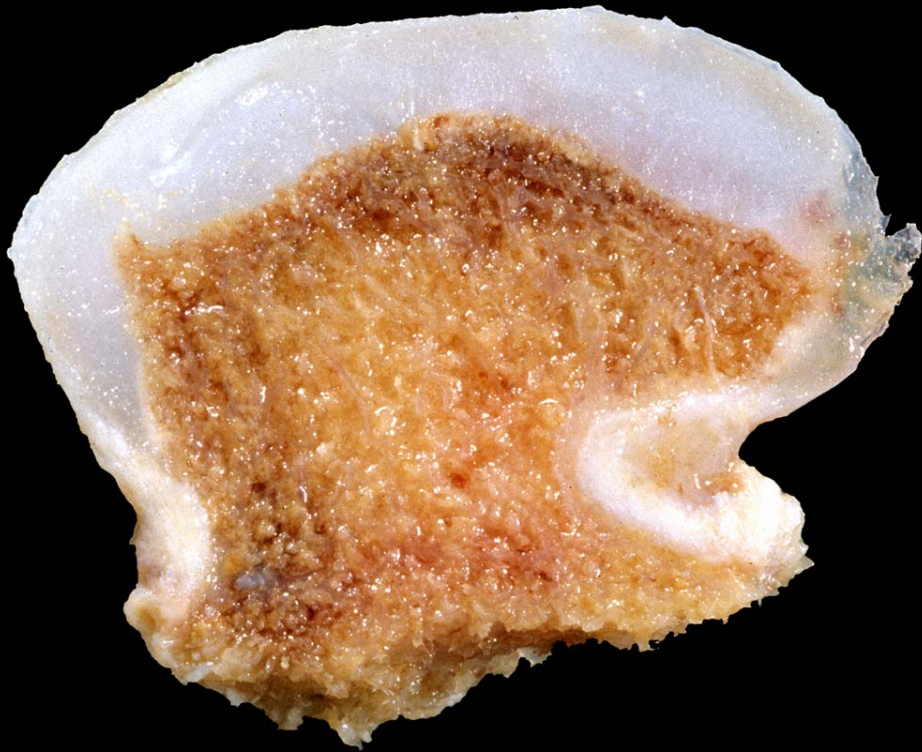

# Osteochondroma



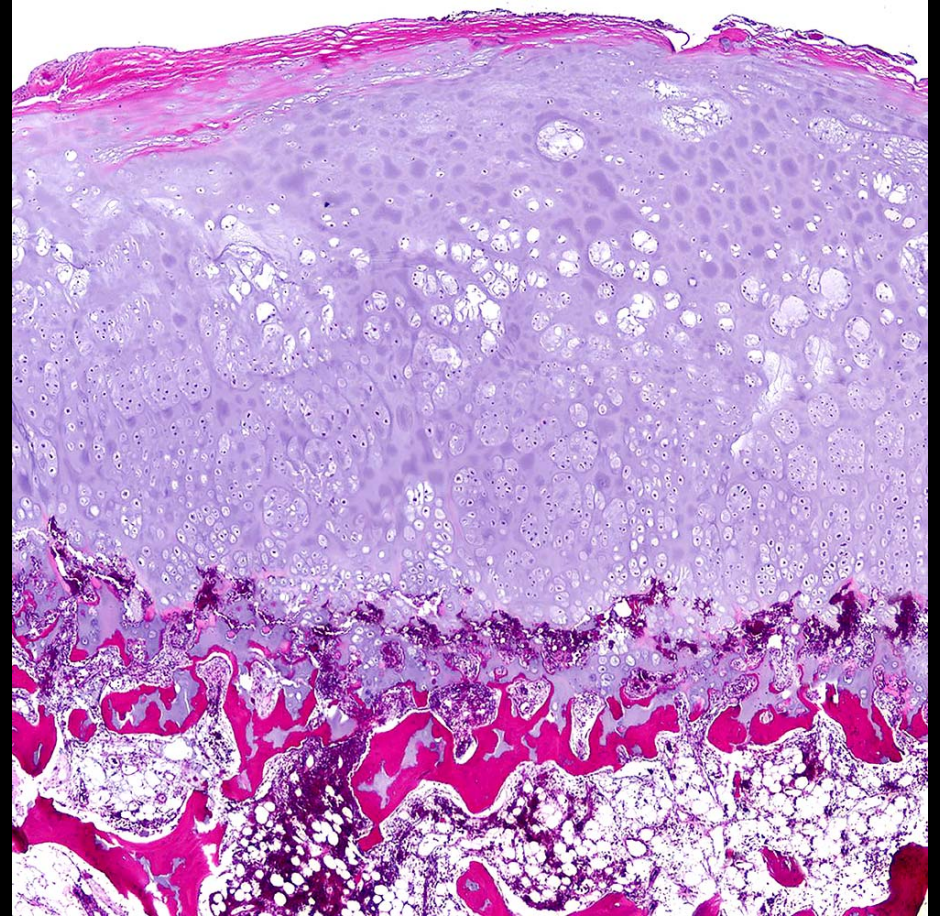
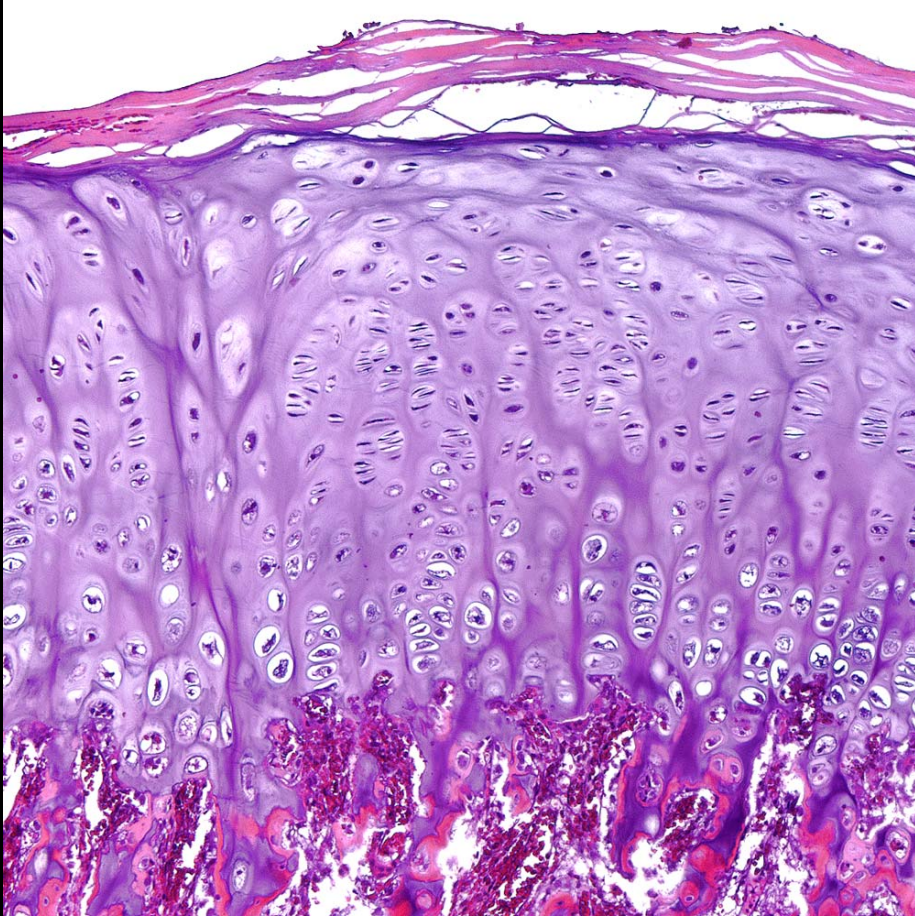


# Osteochondroma





# Osteochondroma





## CASE 6

- Treated with resection
- No recurrence 11 years later



A black and white astronomical photograph of a nebula, likely the Orion Nebula, showing intricate cloud structures and numerous stars. The text "Thank You" is overlaid in the upper right corner in a bold, yellow, sans-serif font.

**Thank You**